PERIAPICAL PATHOLOGY

م.م عبير صلاح سلمان

- Inflammation in the periapical part of the periodontal ligament is similar to that occurring elsewhere in the body, because of the confined space within which the process develops, a particular feature of inflammation in this site is that the adjacent bone and occasionally the root apex, may resorb.

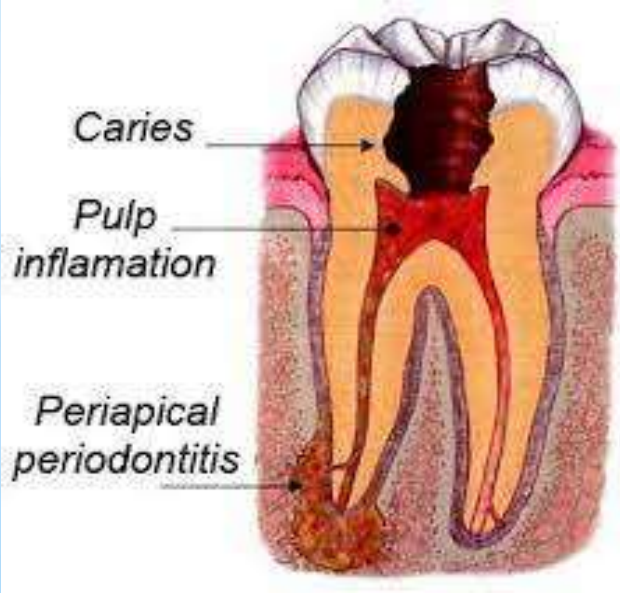

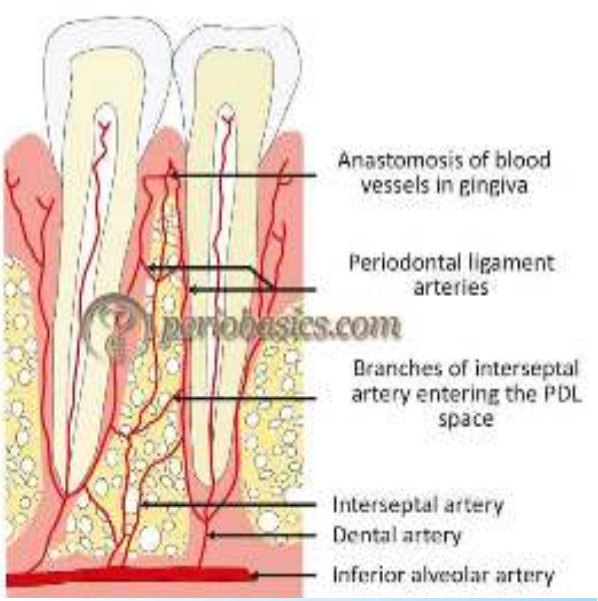

From its origin in the pulp, the inflammatory process extends into the periapical tissues, where it may present as a granuloma or cyst (if chronic) or an abscess (if acute). Acute exacerbation of a chronic lesion may also be seen.

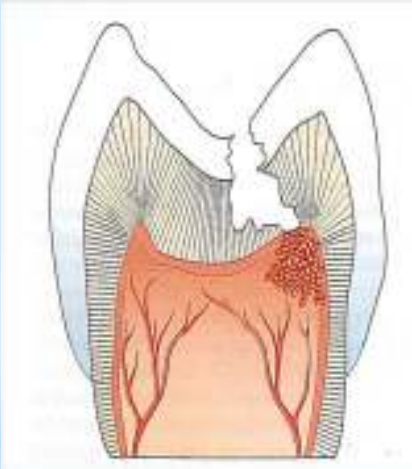

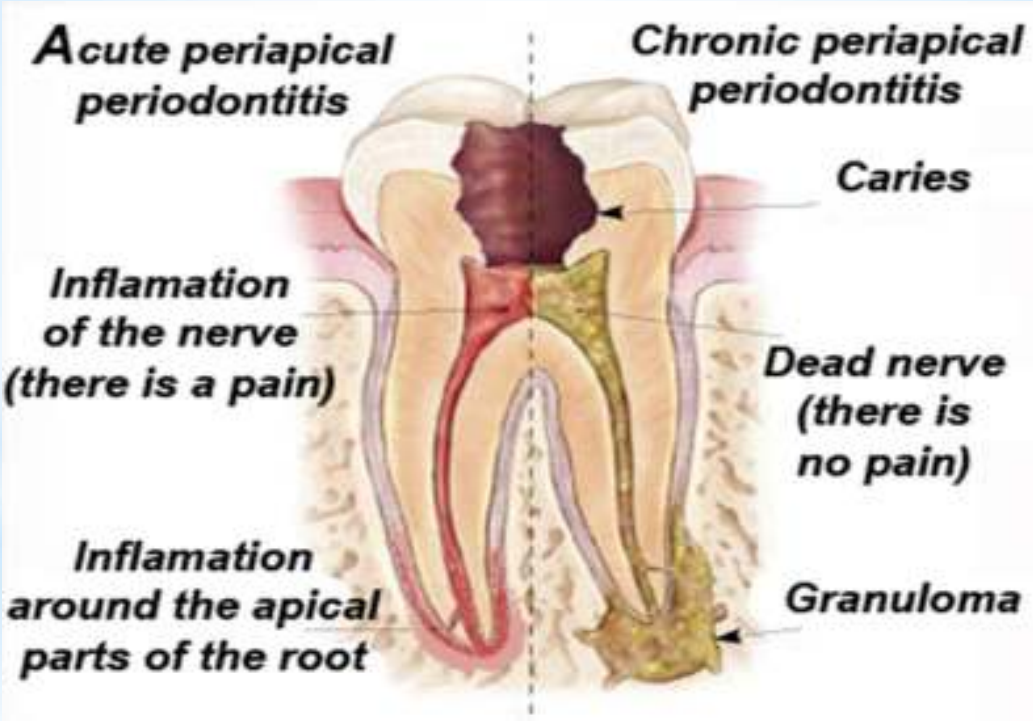

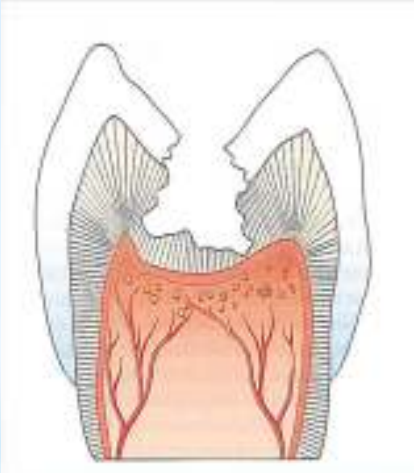

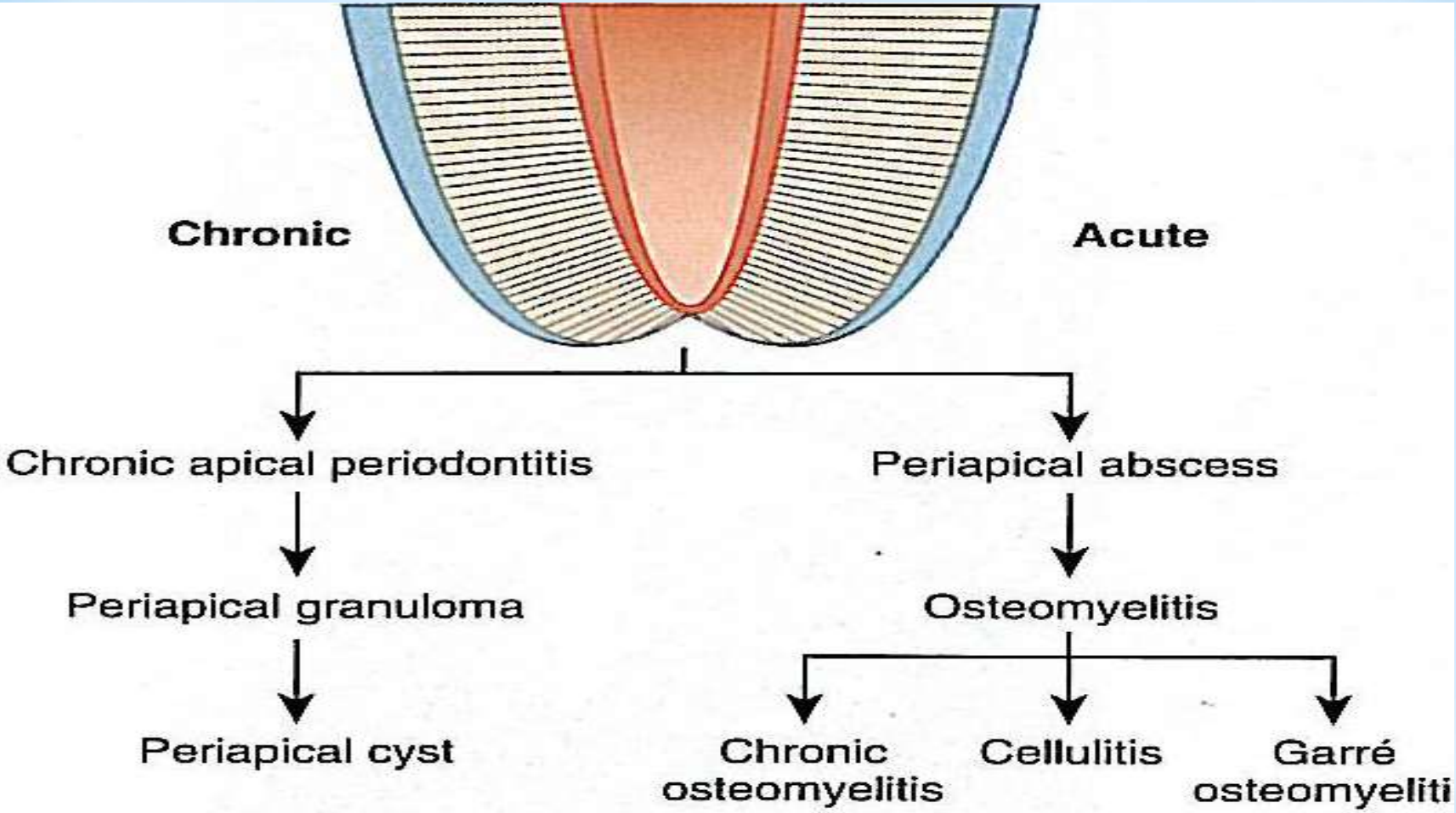

Periapical infections. Chronic and acute pathways that untreated infections and their accompanying clinical lesions may take, depending on the type of the preceding pulpitis, virulence of the bacteria, and the presence or absence of drainage.

Chronic apical periodontitis (periapical granuloma)

- The term periapical granuloma refers to a mass of chronically or sub acutely inflamed granulation tissue at the apex of a non vital tooth.

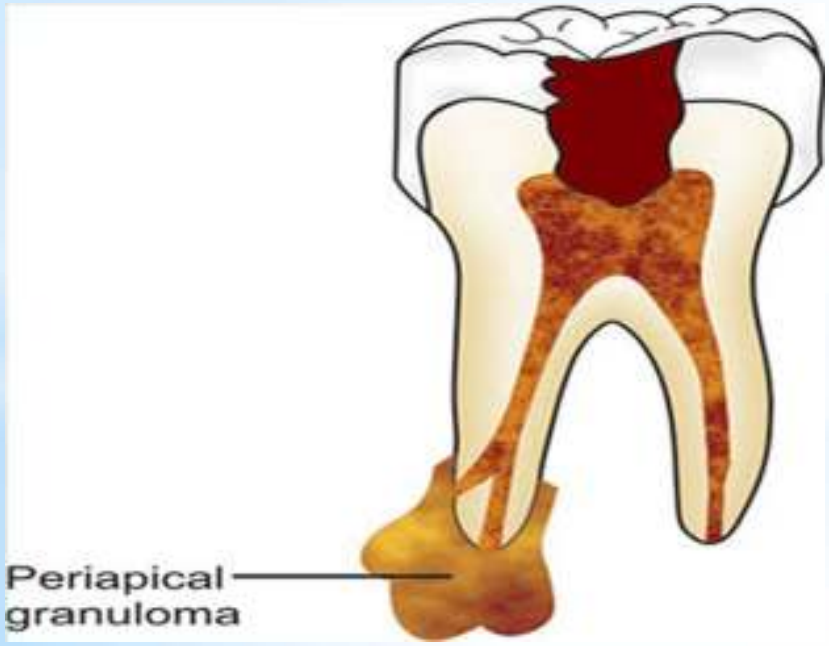

* External resorption. Extensive irregular destruction of both roots of the mandibular second molar associated with chronic periodontitis.

Periapical Granuloma

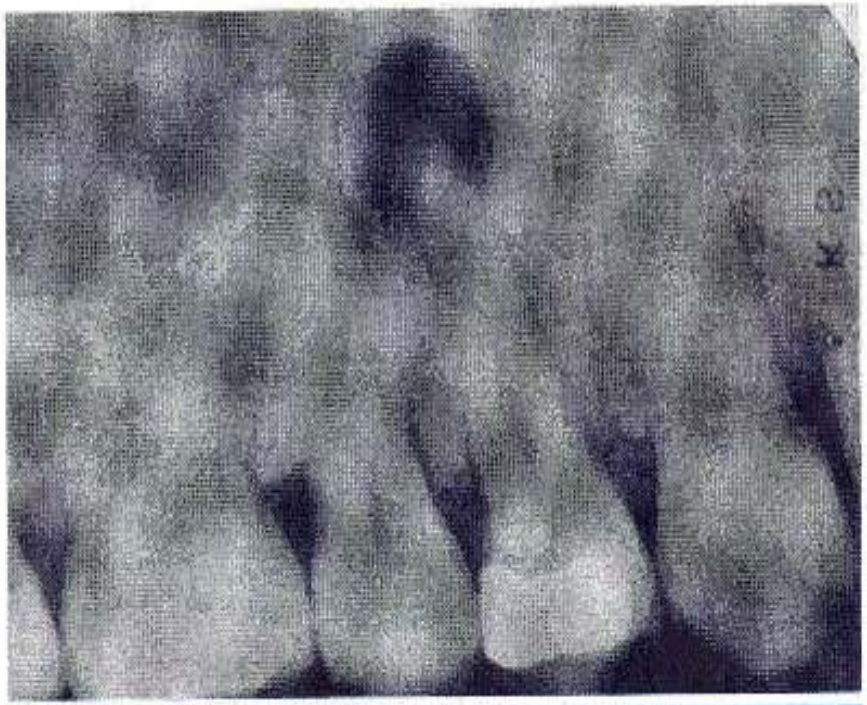

Figure 3-16 • **Periapical granuloma.** Well-defined radiolucency associated with the apex of the maxillary first bicuspid. (Courtesy of Dr. Frank Beylotte.)

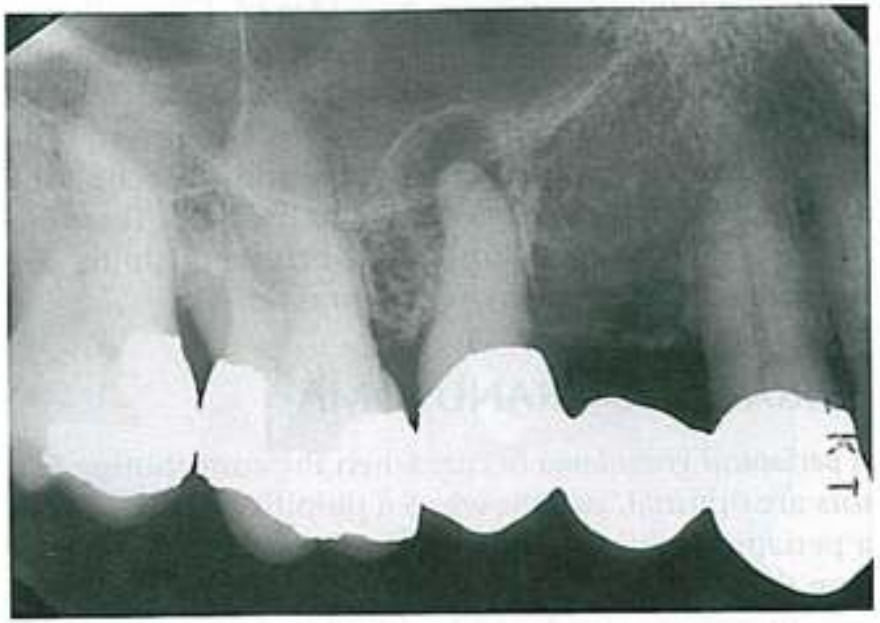

FIGURE 3-24

Periapical granuloma. Radiograph of a periapical granuloma with a prominently corticated outline of the interface with normal bone that is in continuity with the lamina dura of the associated tooth.

Histopathological features

- Periapical granulomas consist of an inflamed granulation tissue surrounded by fibrous connective tissue wall.
- The central part of the lesion contains macrophages with foamy cytoplasm caused by the phagocytosis of cholesterol.

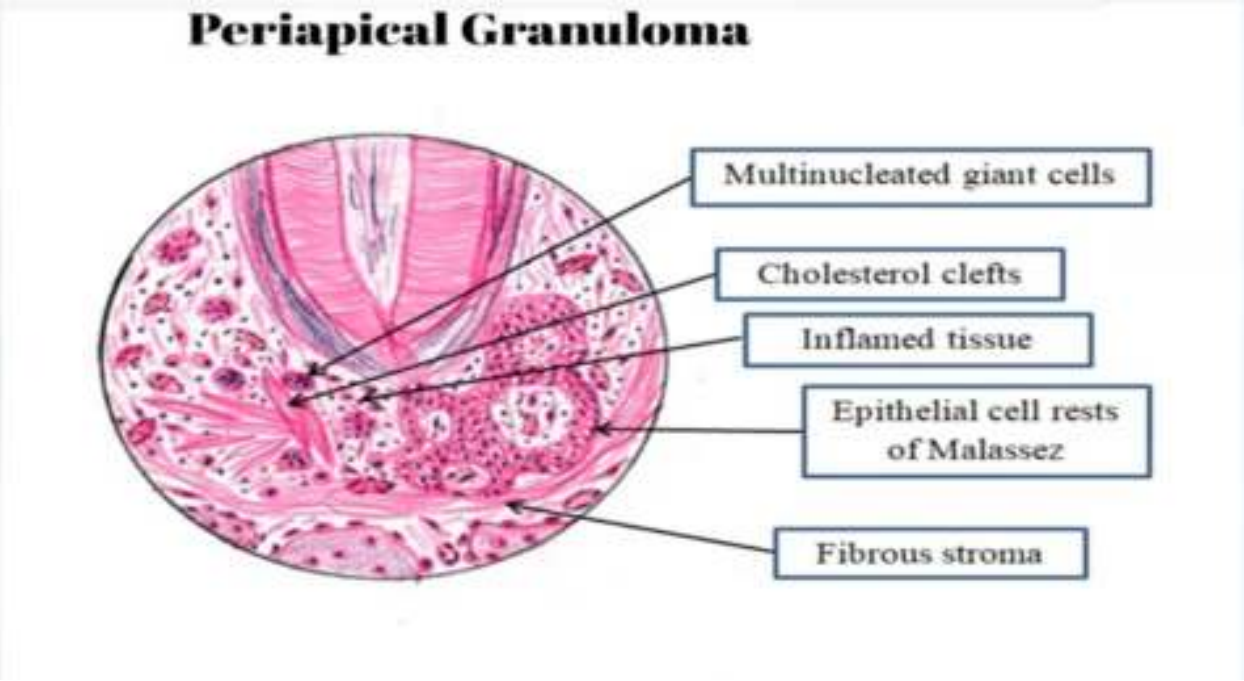

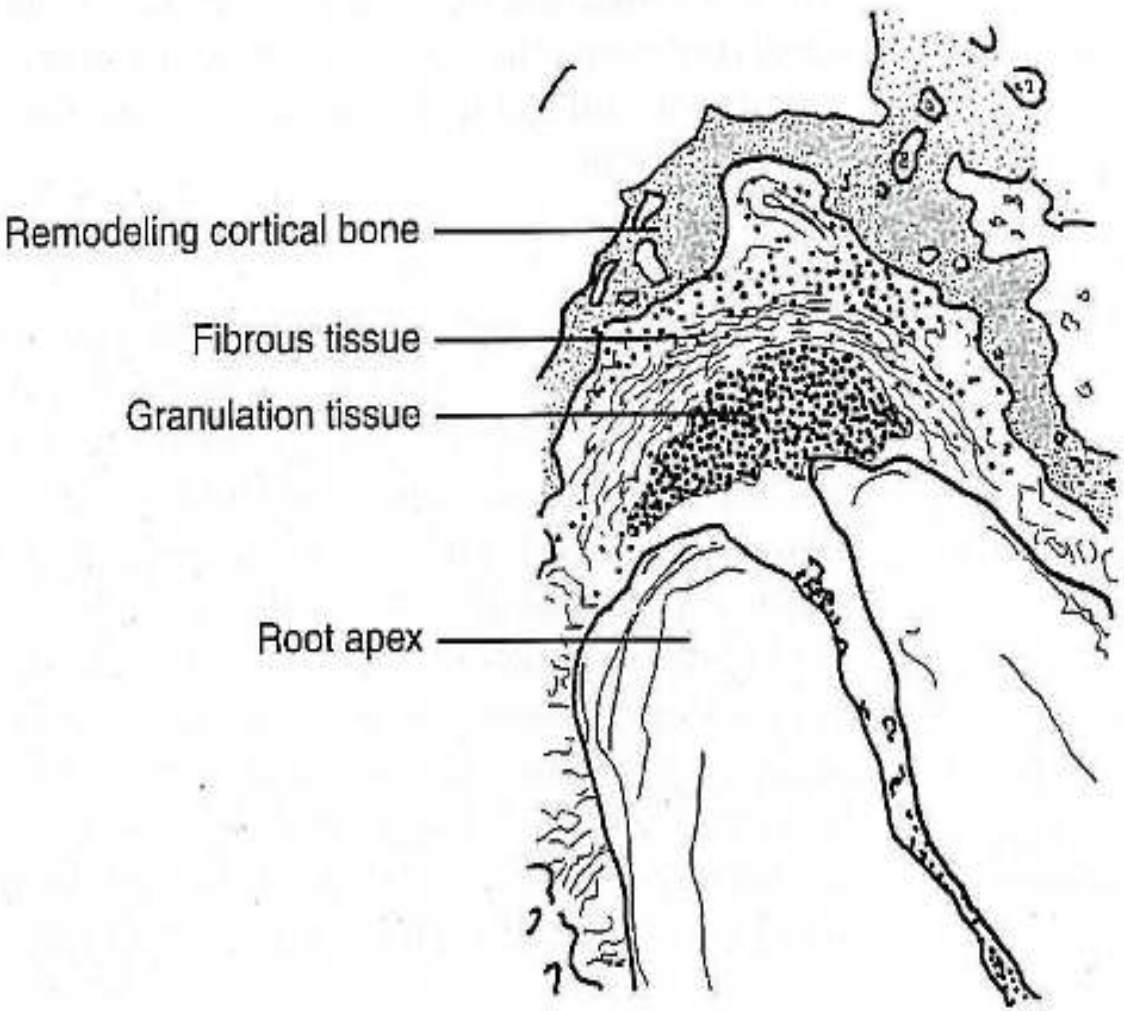

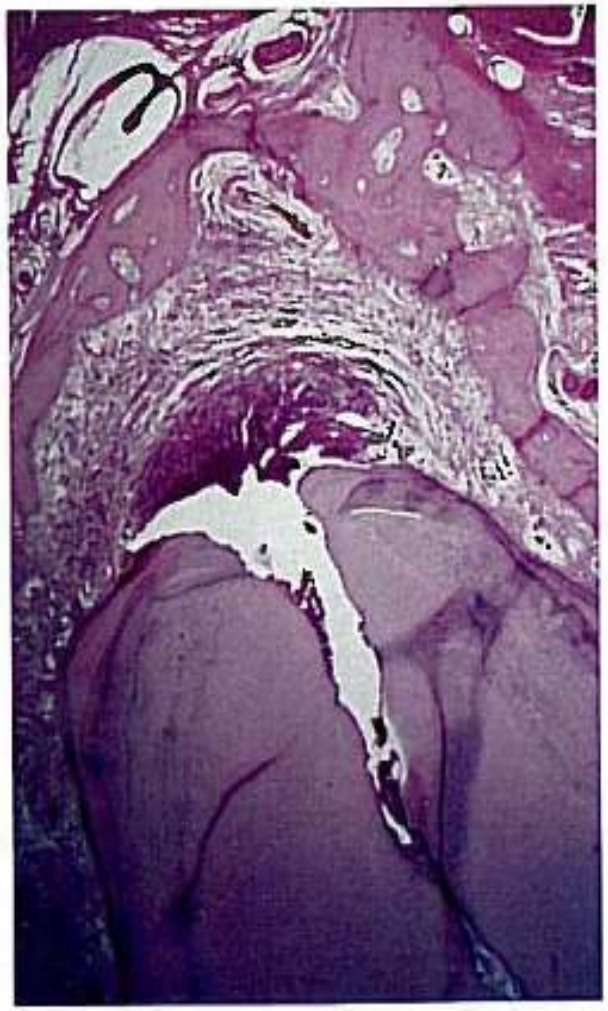

[redacted]

FIGURE 3-25

Periapical granuloma. Microscopic appearance of the early stage of granuloma development, exhibiting granulation tissue at the apical foramen surrounded by fibrous tissue and an outer zone of cortical bone.

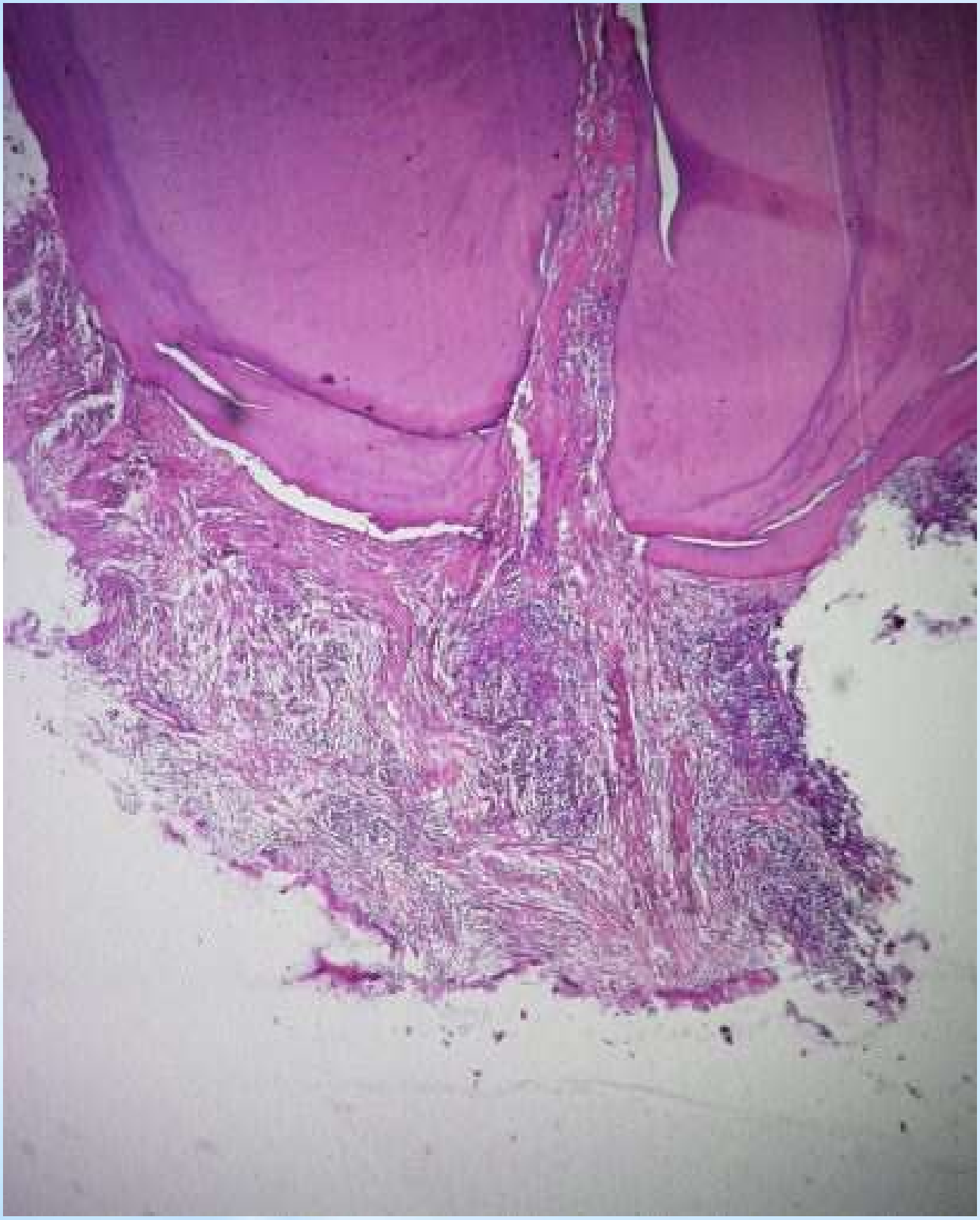

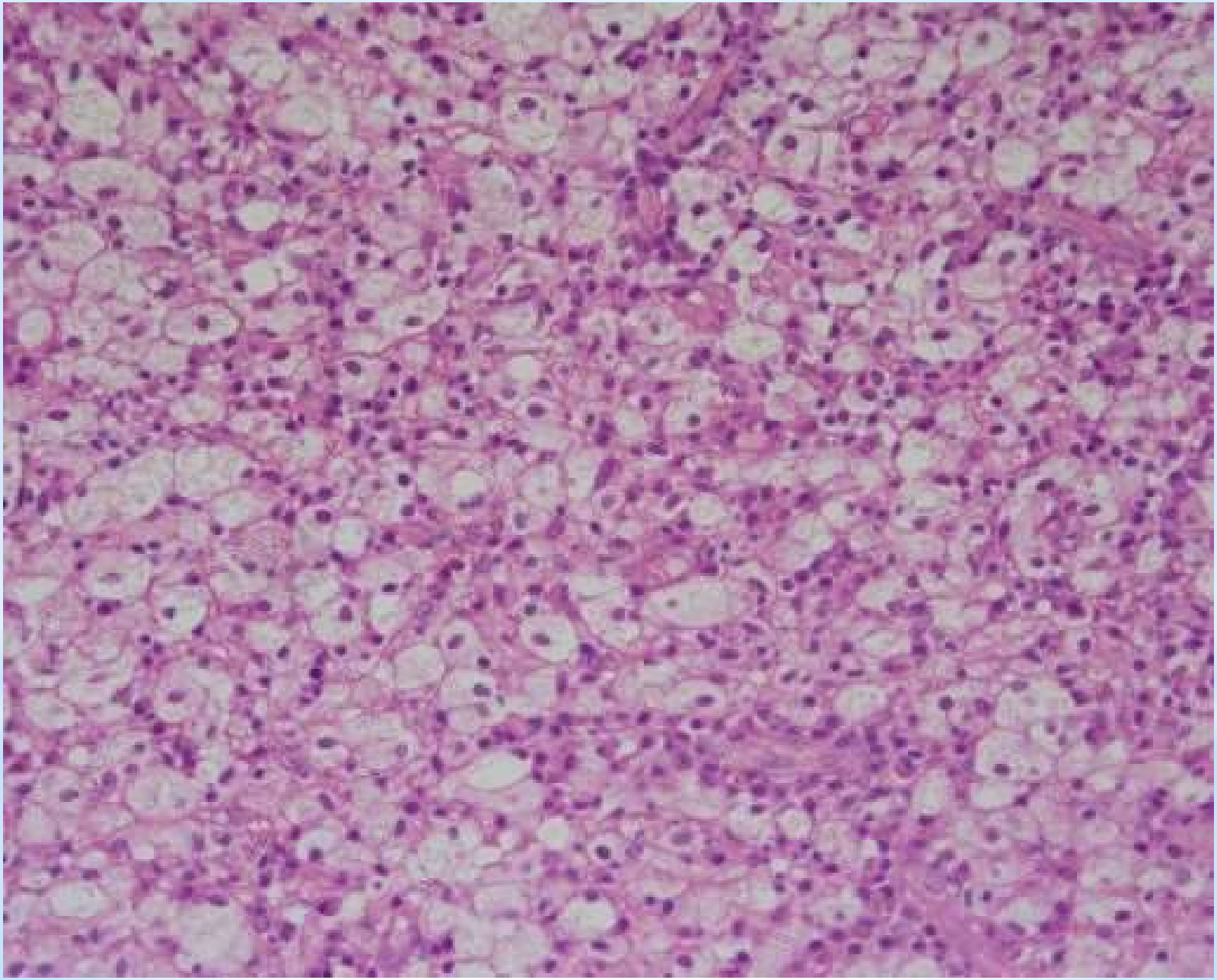

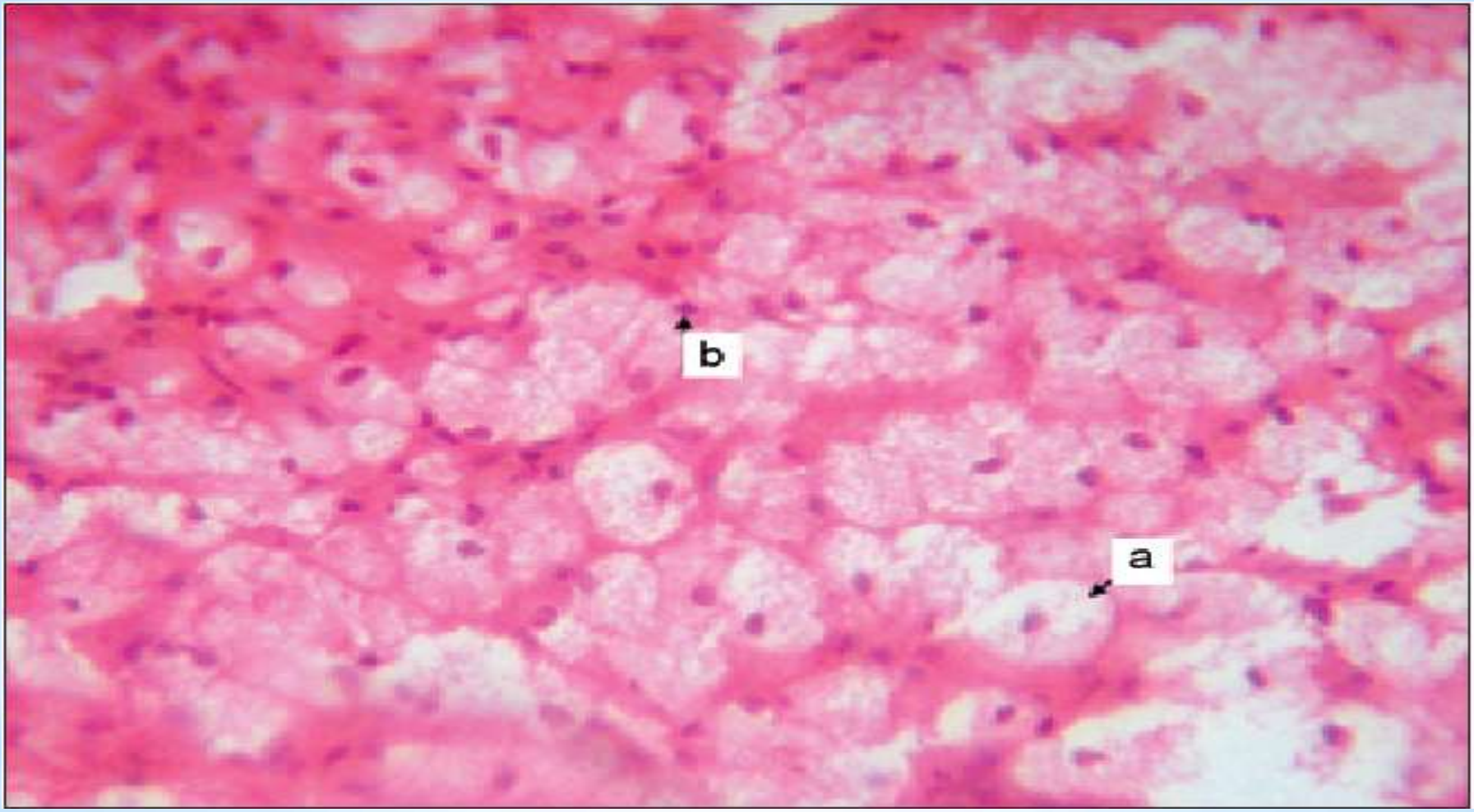

Figure 1: Early stage of periapical granuloma with predominantly foamy macrophages (a) and lymphocytes (b) [H and E, ×40]

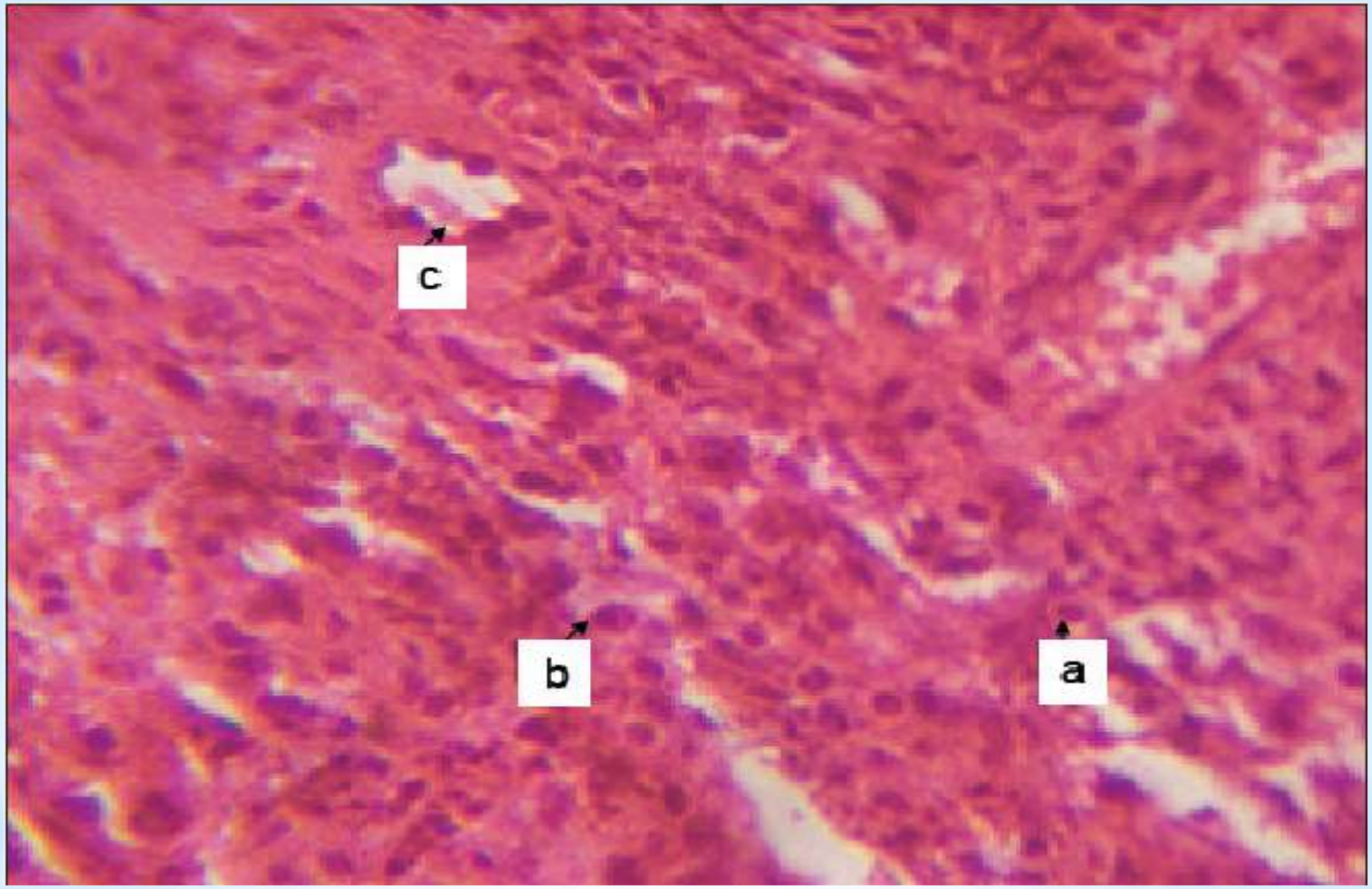

Figure 2: Intermediate stage of periapical granuloma with prominent lymphocytes (a), plasma cells (b) and blood vessels (c) [H and E, ×40]

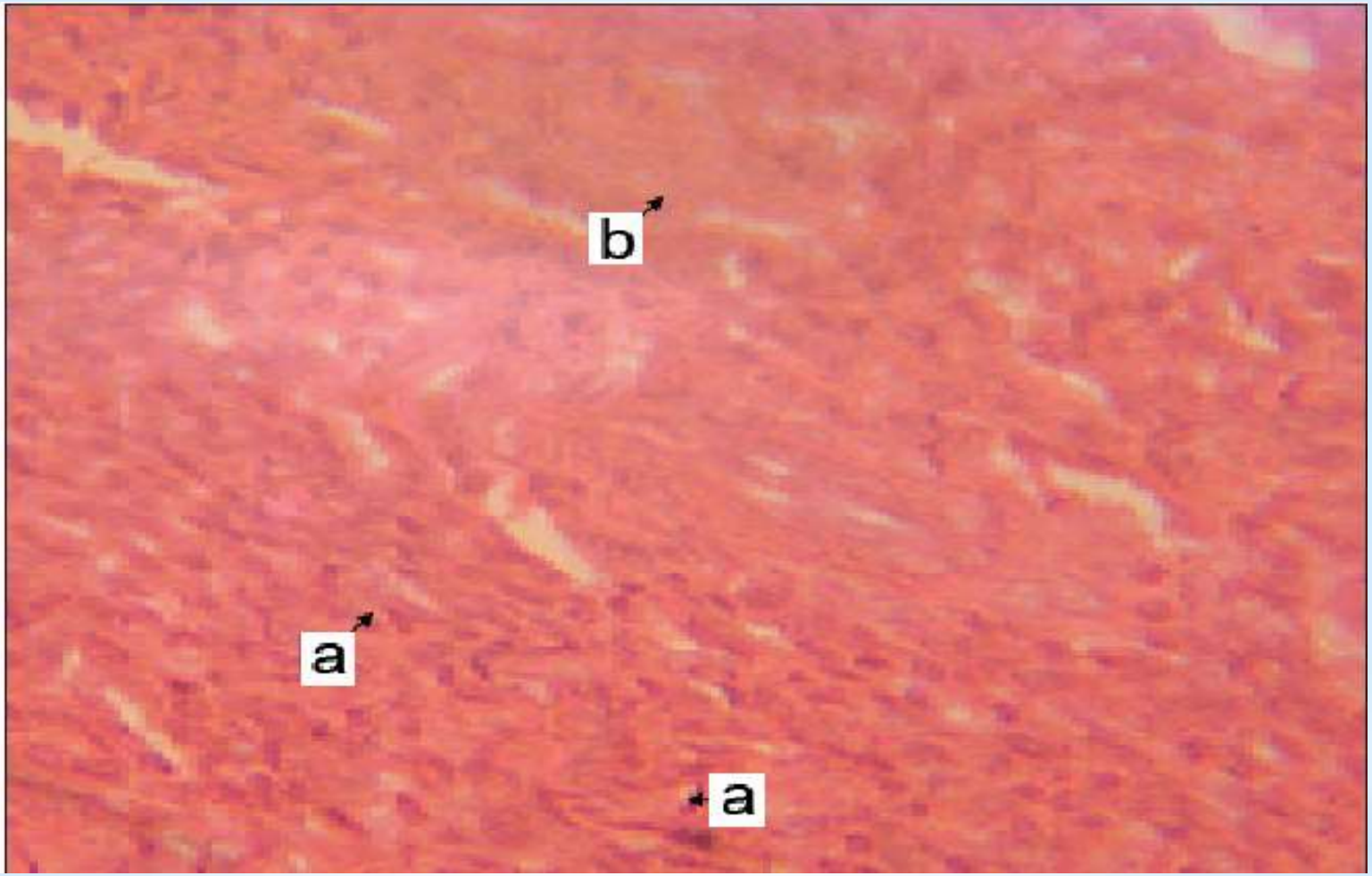

Figure 3: Late stage of periapical granuloma with prominent fibroblasts (a) in hemosiderin pigmented fibrotic stroma (b) [H and E, ×40]

Acute periapical abscess

Drainage pathways of acute periapical infections. The location of the various points of drainage is determined by the anatomic location of the root apex. Common locations are *(1)* surface of gingiva (parulis), *(2)* palate (palatal abscess), *(3)* maxillary sinus, *(4)* soft tissue spaces superior (maxilla) and inferior (mandible) to buccinator muscle (cellulitis), and *(5)* floor of the mouth (Ludwig angina).

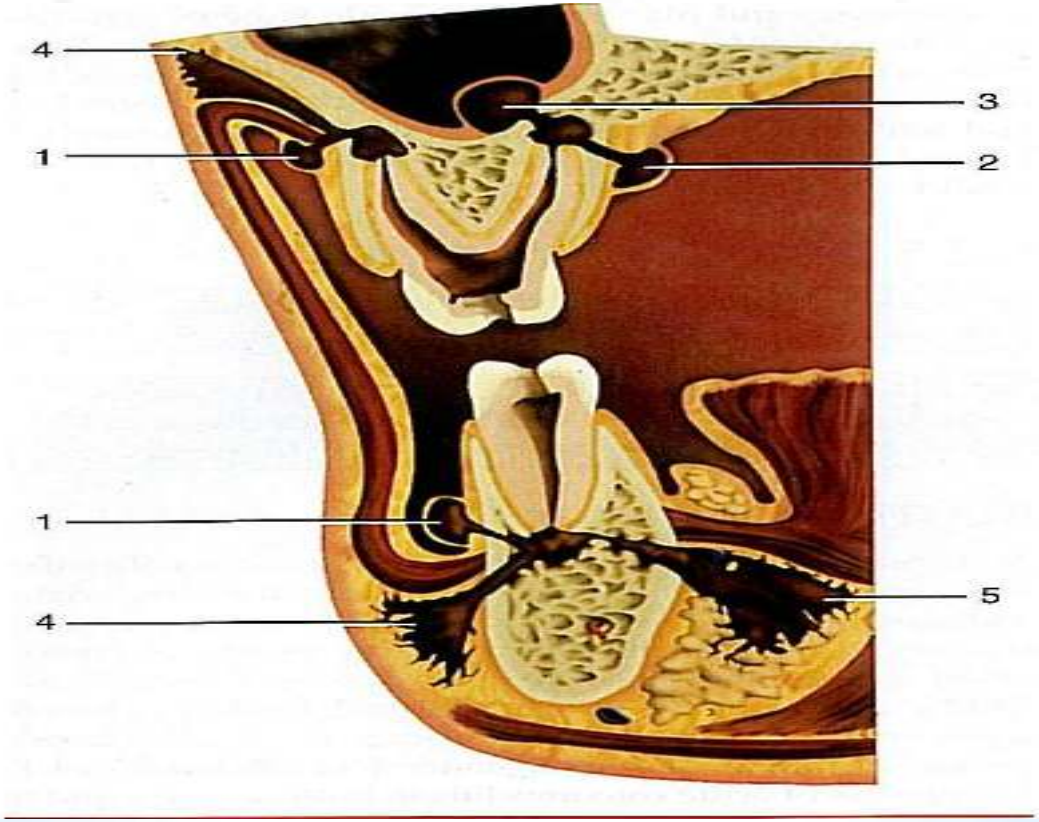

* Periapical abscess.
  Bilateral soft-tissue swelling of the anterior palate.

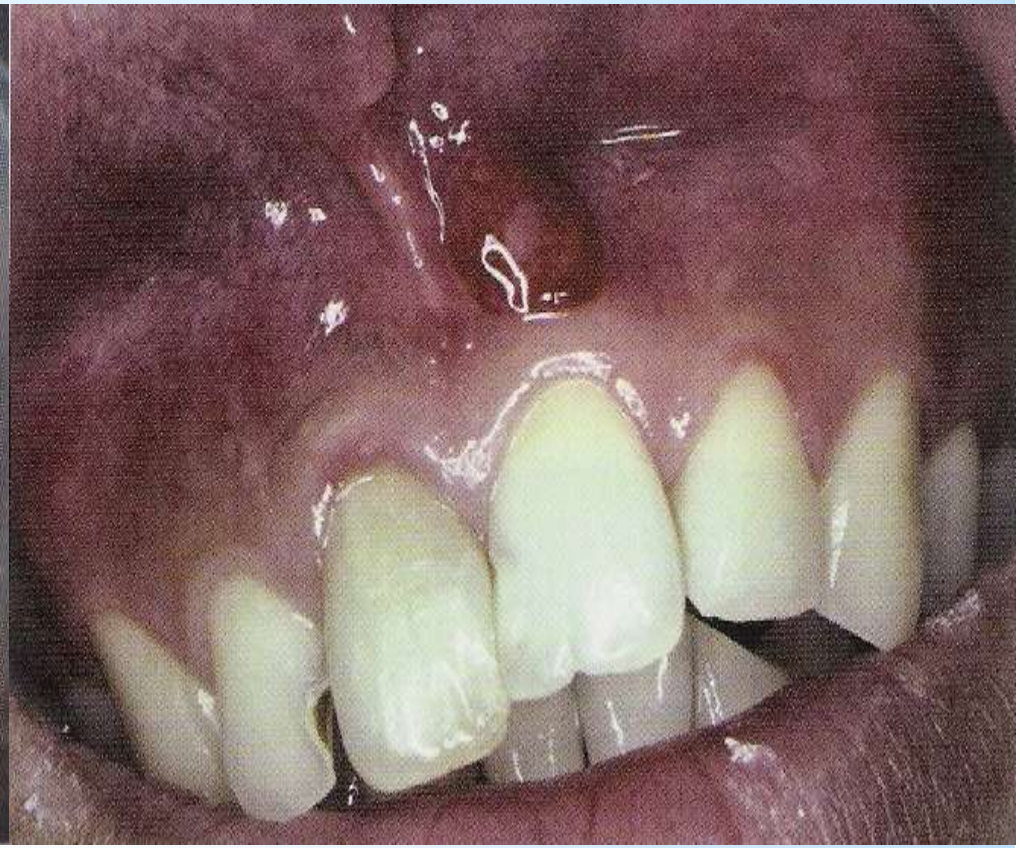

*Gum boil

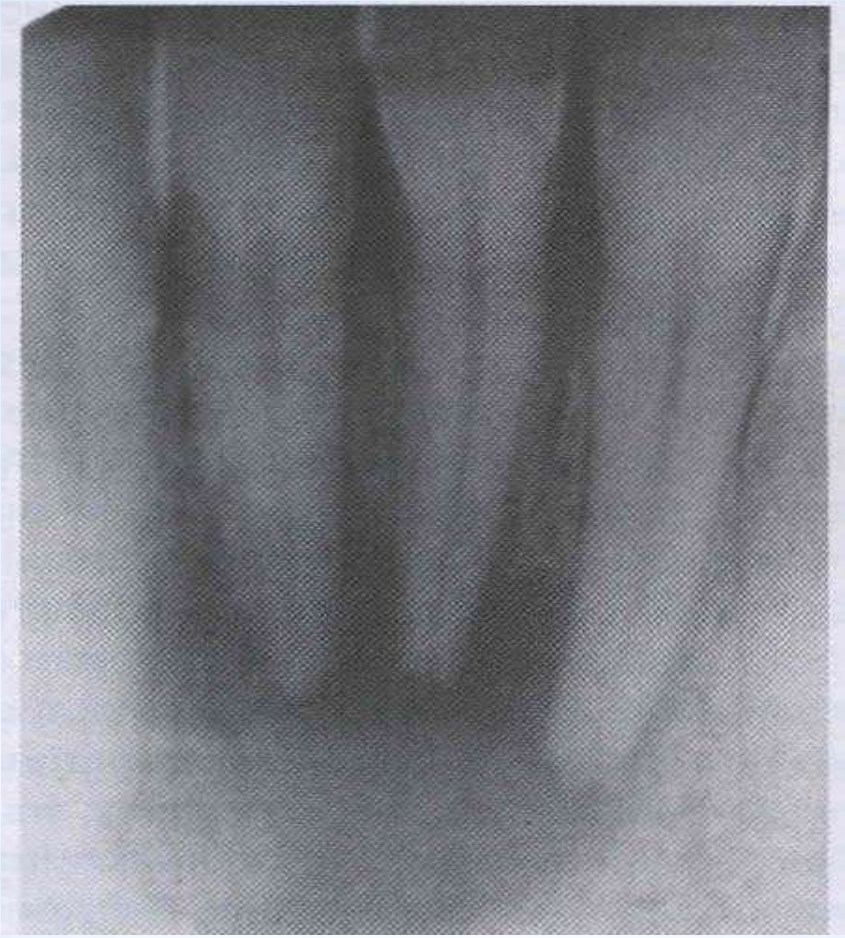

* Periapical abscess, periapical radiolucency associated with the nonvital mandibular lateral incisor.

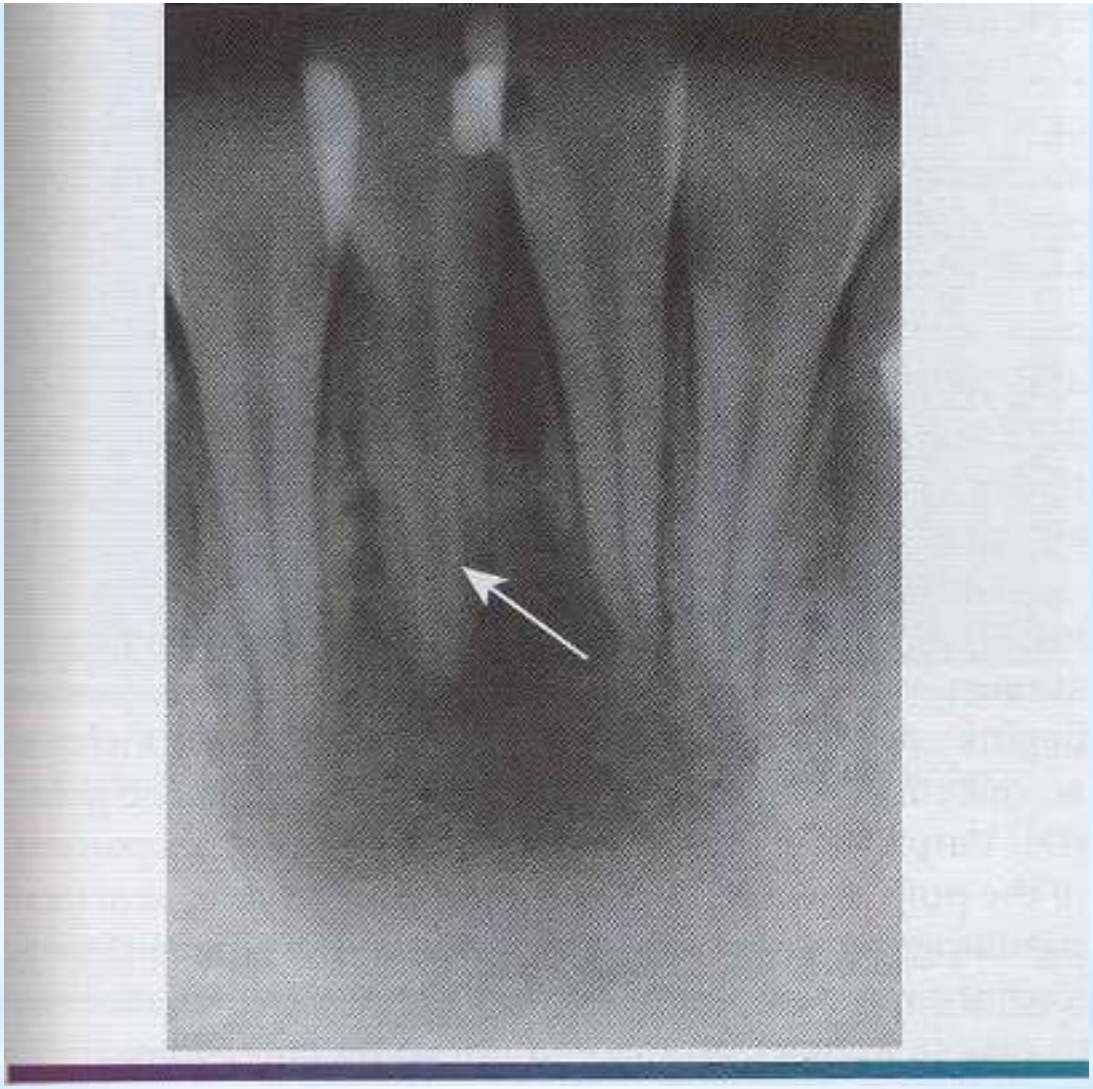

* Physiologic secondary dentin. Periapical abscess with all four teeth non responsive to electric pulp testing.

Increased deposition of physiologic secondary dent in on the right central incisor *(arrow) delineated the origin of the infection*; endodontic treatment of this tooth resolved the lesion.

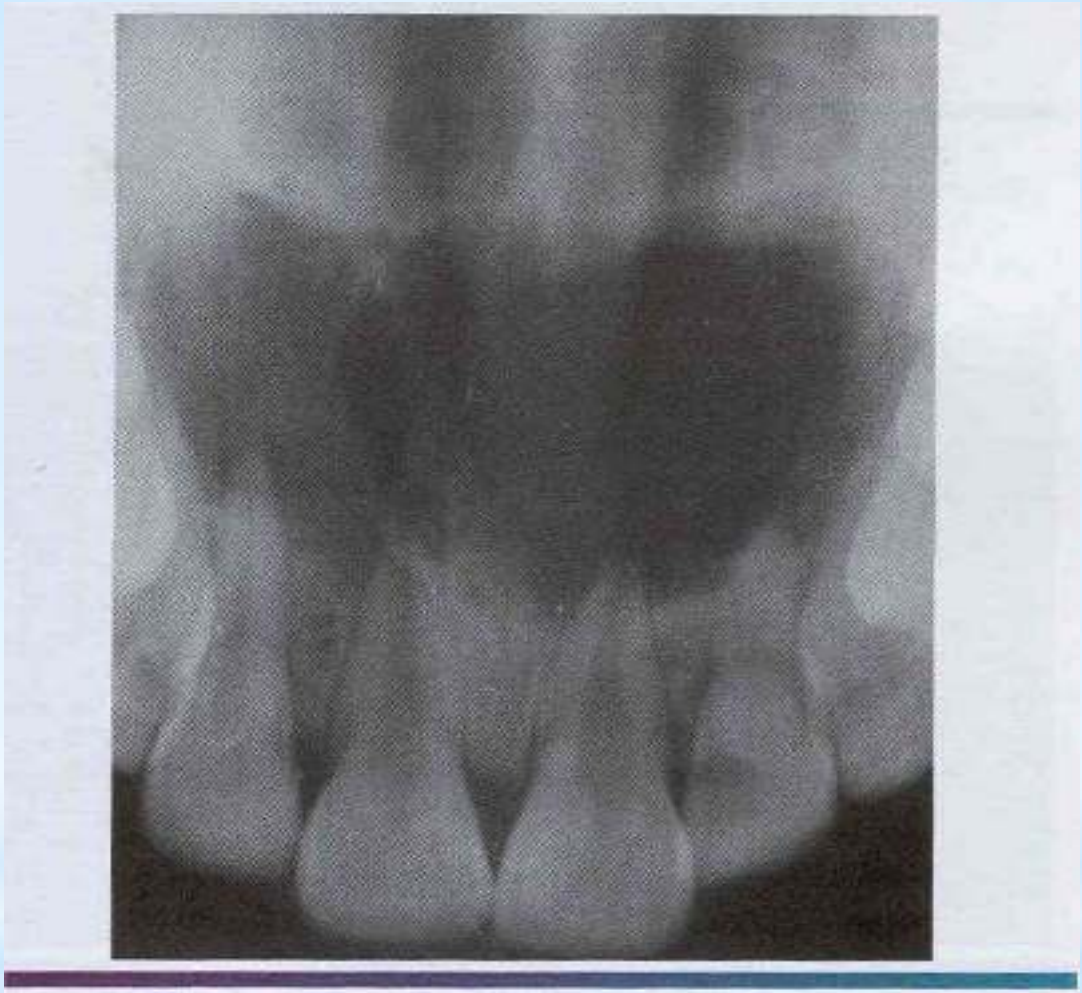

* Periapical abscess. Multiple, overlapping radiolucencies of the anterior maxilla are present. All four maxillary incisors exhibit pulpal necrosis.

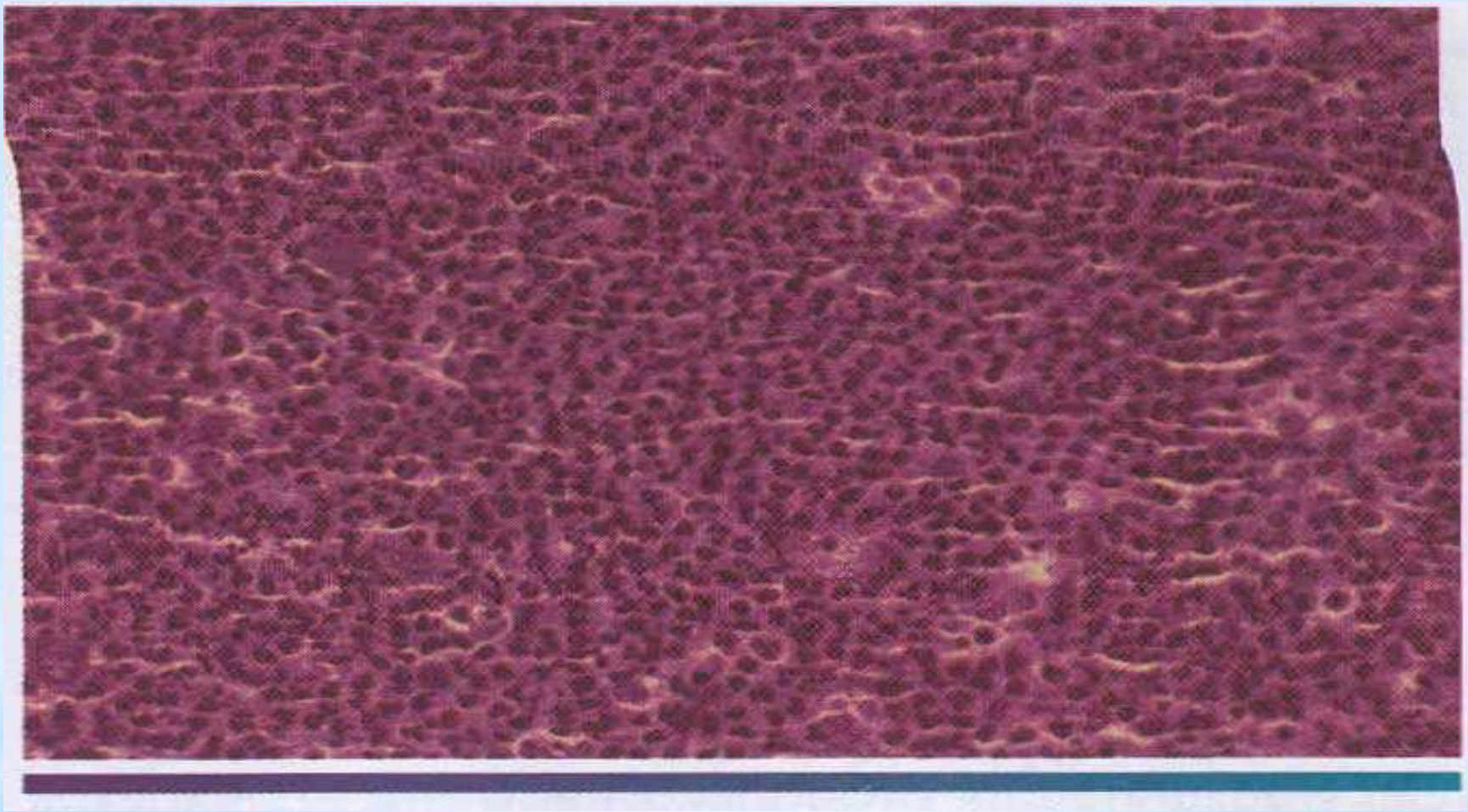

* Periapical abscess. Sheet of polymorphonuclear leukocytes intermixed with scattered histiocytes .

A

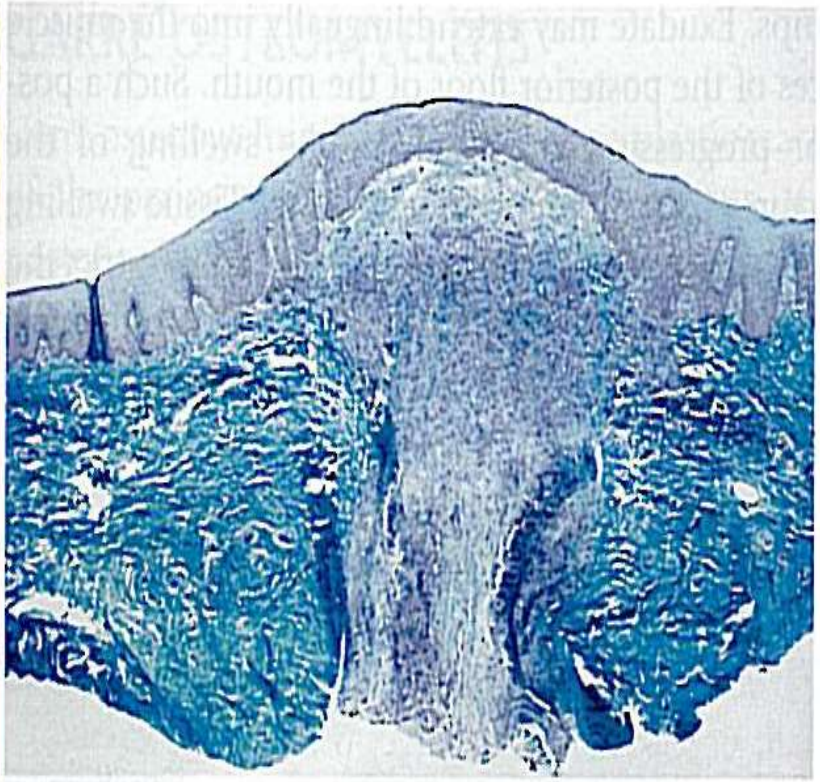

B

[redacted]

Parulis. A, Patient with a small nodule represents the opening of a draining sinus tract on the gingiva adjacent to a nonvital left mandibular cuspid. **B,** Microscopic appearance of a gingival nodular swelling, demonstrating the central core of purulent exudate (sinus tract) exerting pressure beneath the epithelium that is near the point of rupture (Trichrome stain).

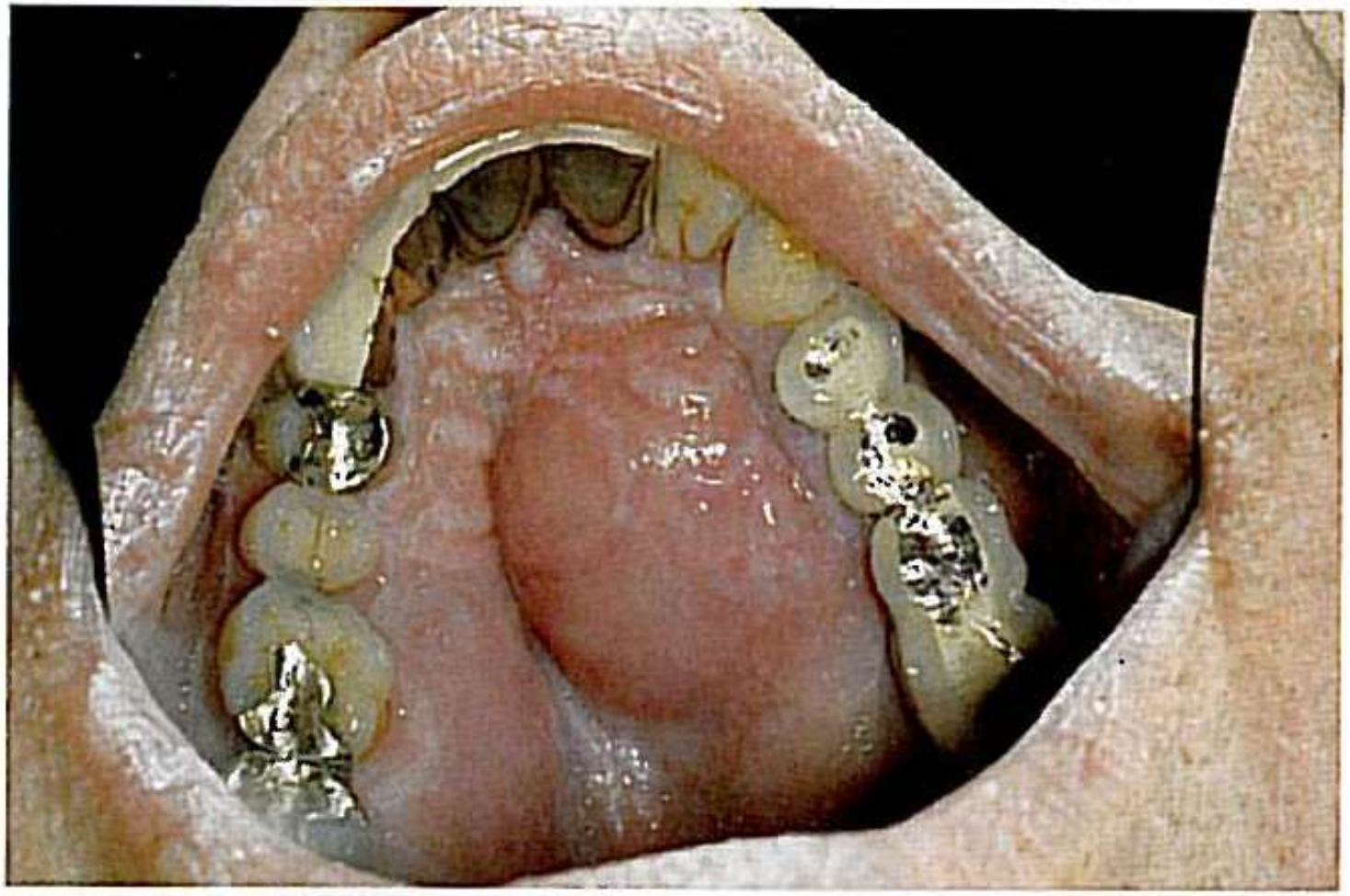

Palatal abscess. A large fluctuant swelling of the palate caused by the drainage of purulent exudate into the submucosal tissue from an apical area of nonvital premolars.

[redacted]

Oroantral fistula. An open communication between the maxillary sinus (antrum) and the oral cavity is present on the edentulous alveolar ridge after the extraction of a molar with a long-standing periapical lesion that involved the sinus floor.

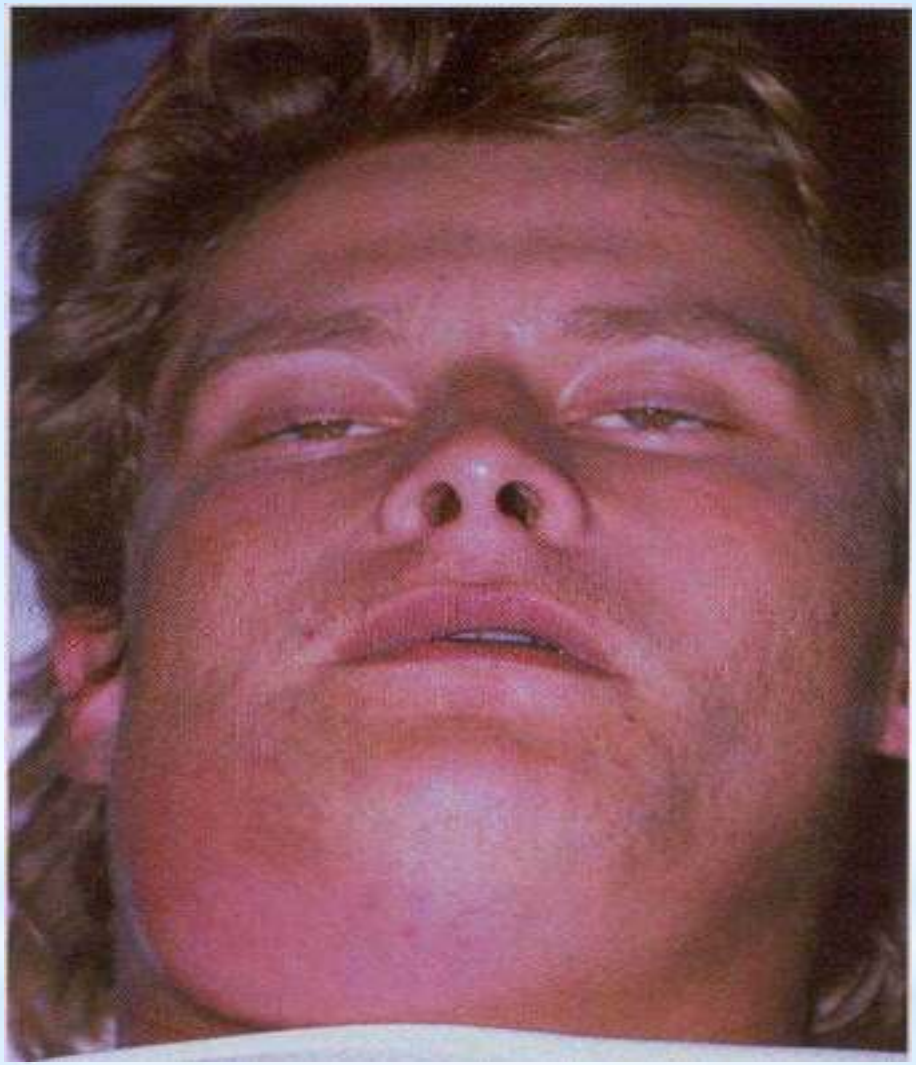

* Ludwig's angina.
Soft-tissue swelling of the right submandibular region.

* Cellulitis involving canine space .Erythematous and edematous enlargement of the left side of the face with involvement of the eyelids and conjunctiva. Patients with odontogenic infections involving the canine space are at risk for cavernous sinus thrombosis.

Cutaneous sinus

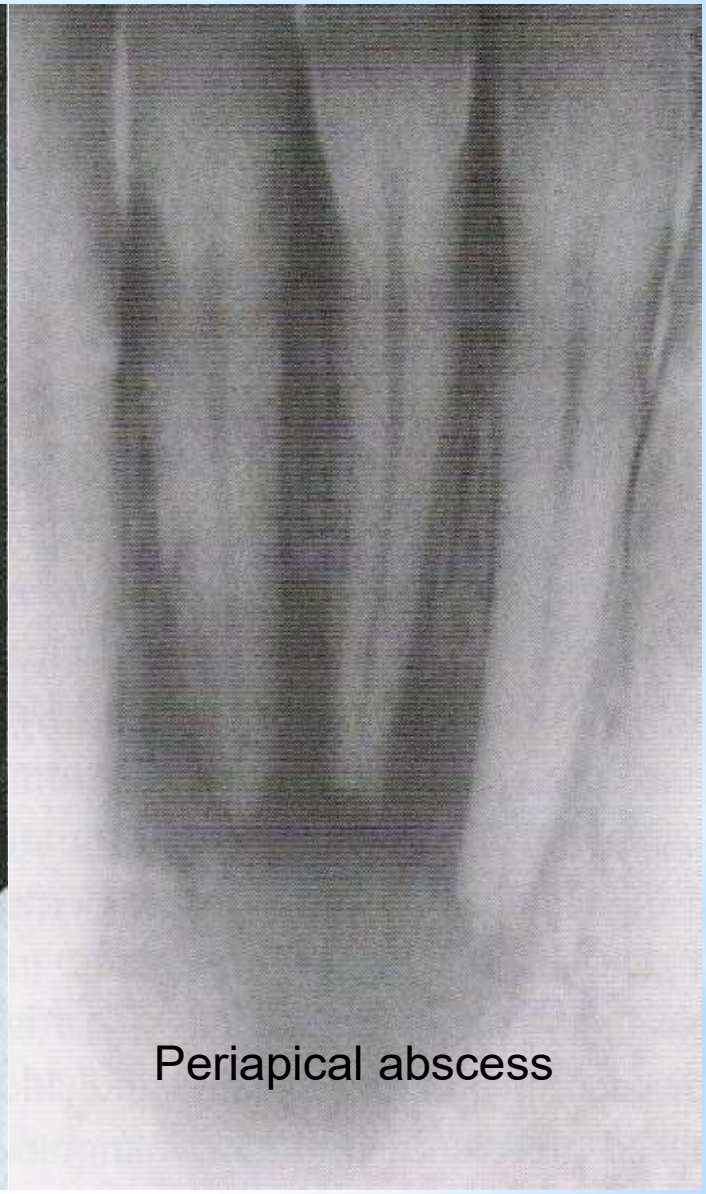
Periapical abscess

Periapical cyst

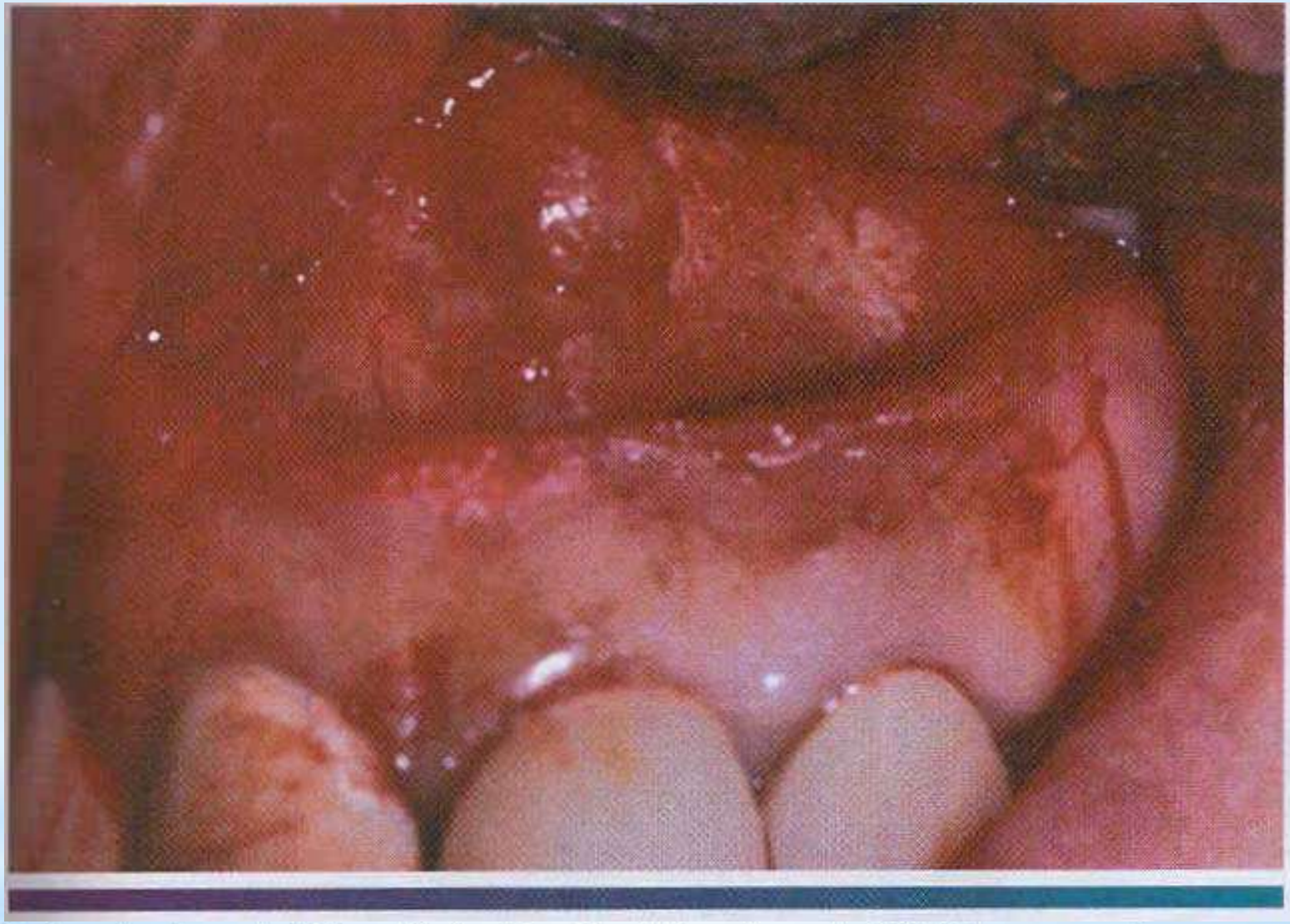

* Periapical cyst. The clinically significant cyst. Which was not appreciated fully on the radiograph.

* Periapical cyst. Well-circumscribed radiolucency intimately associated with the apex of the mandibular central incisor. Note the loss of lamina dura in the area of the lesion.

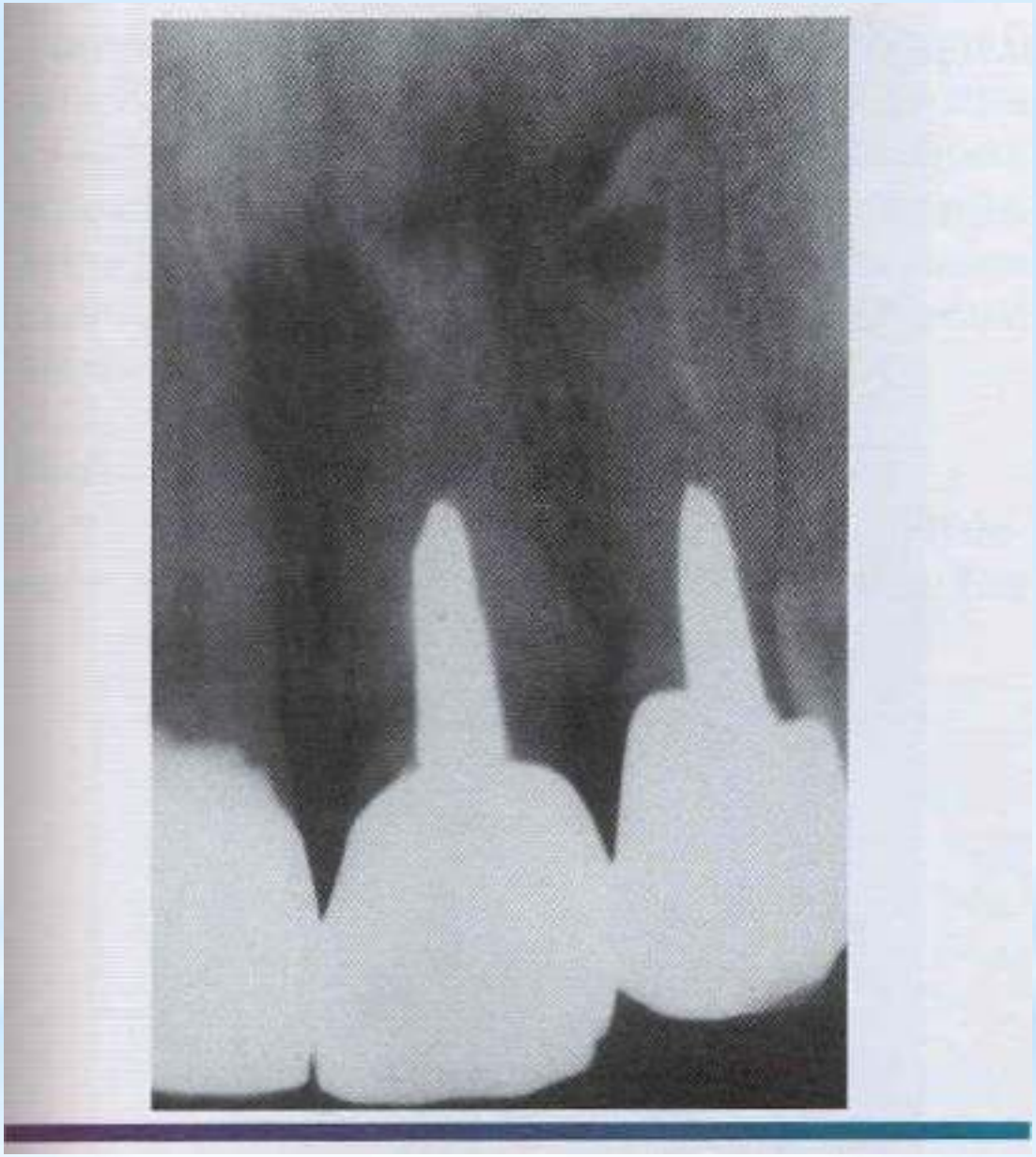

* Periapical cyst. Discrete. Ill-defined radiolucency associated with the maxillary left central incisor.

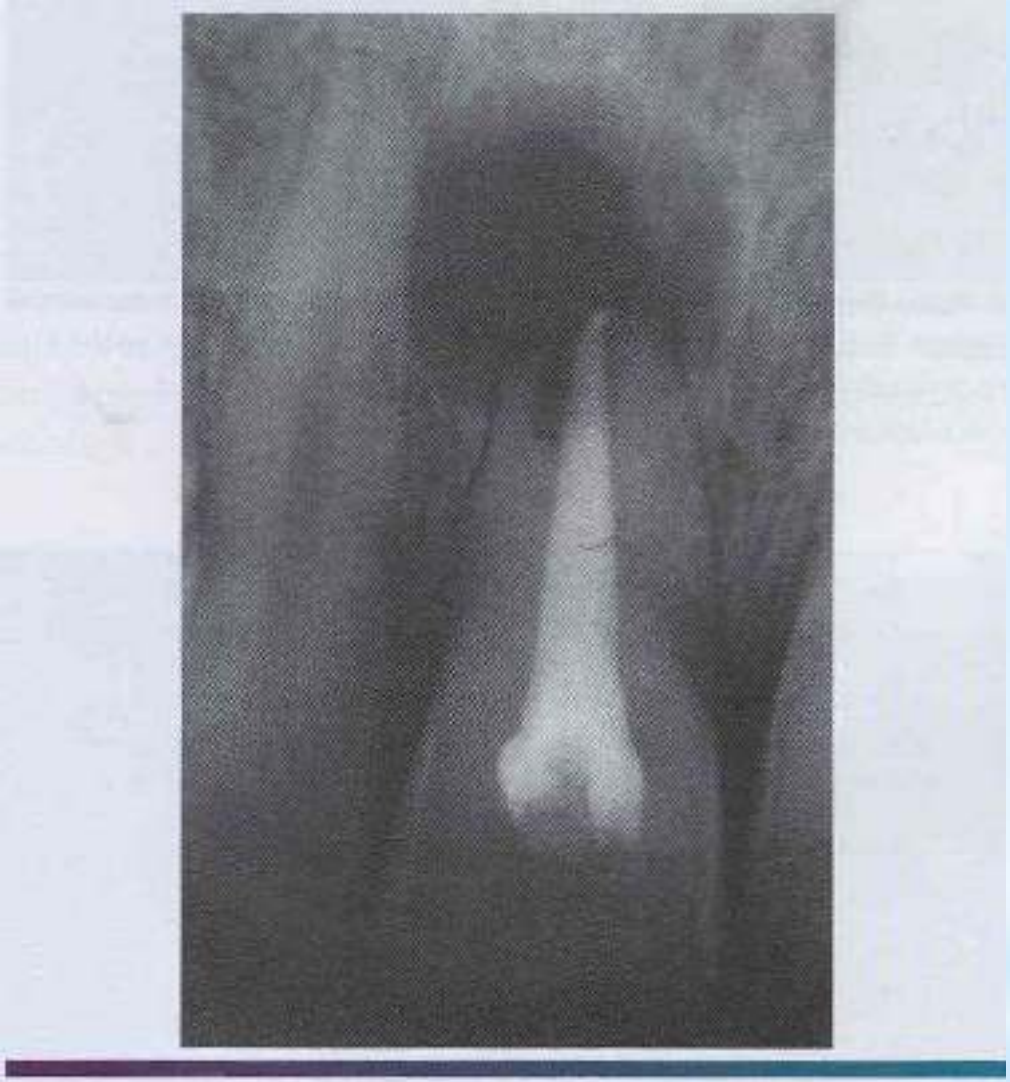

* Periapical cyst. Radiolucency associated with the maxillary central incisor, which exhibits significant root resorption.

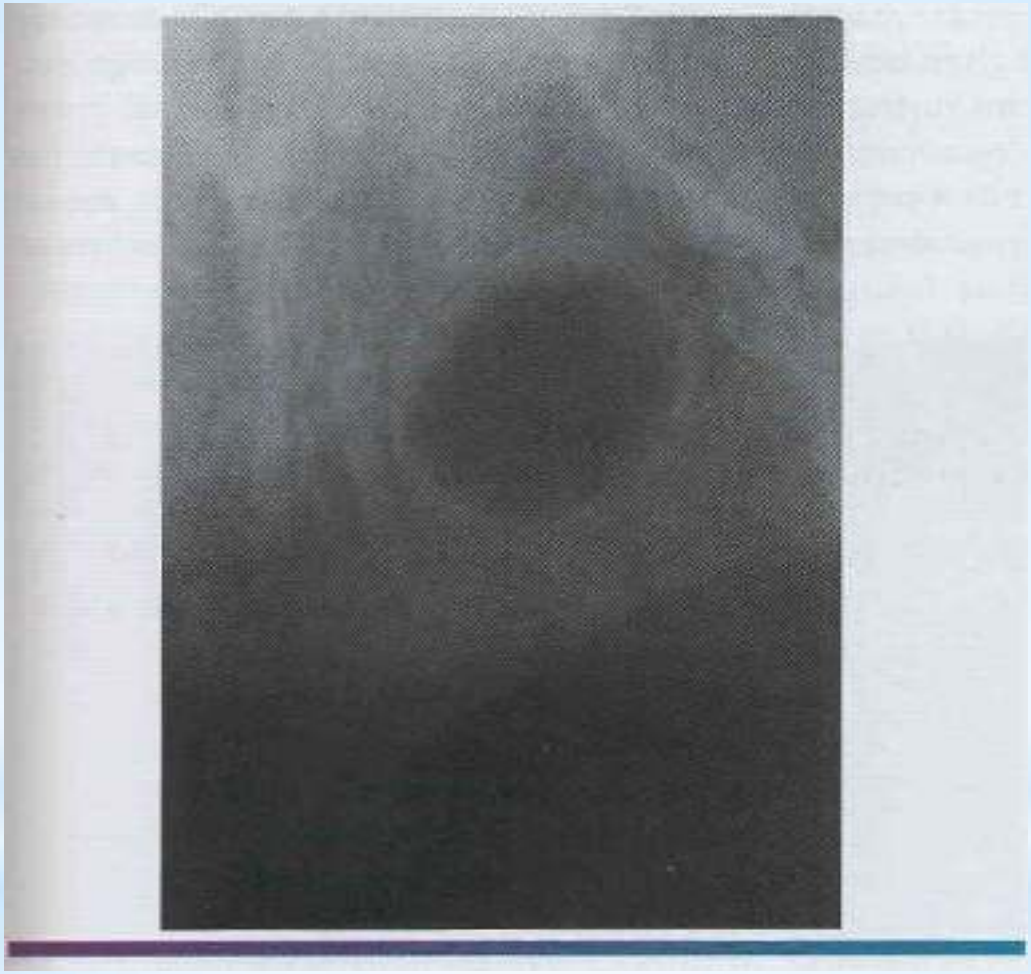

* Residual periapical cyst . persistent radiolucency of the mandibular body at site of previoustooth extraction.

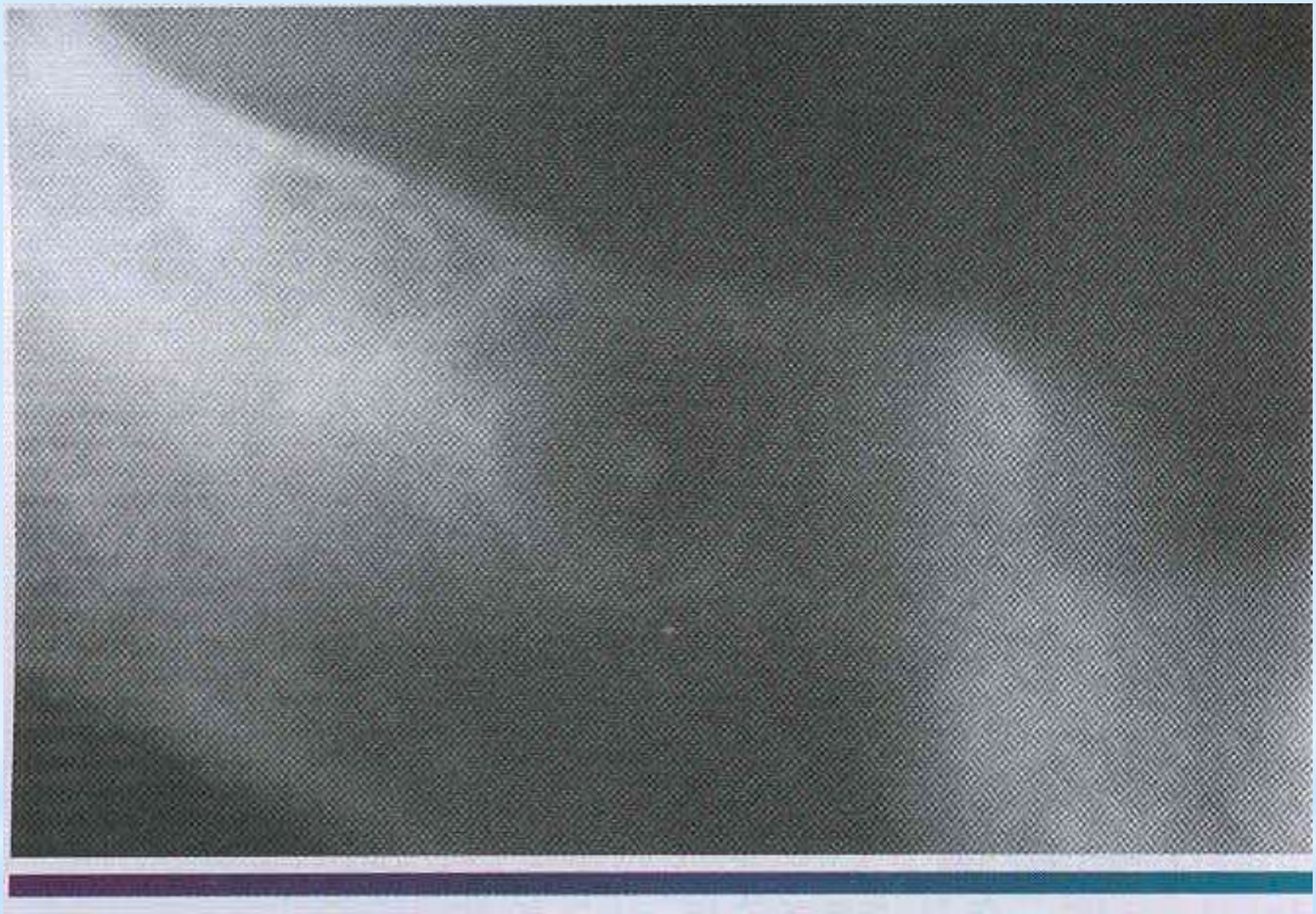

* Residual radicular cyst. Radiolucency with central radiopacity of the right mandibular body.

Lumen (cavity) of cyst
Epithelial lining
Wall (capsule) – made of connective tissue

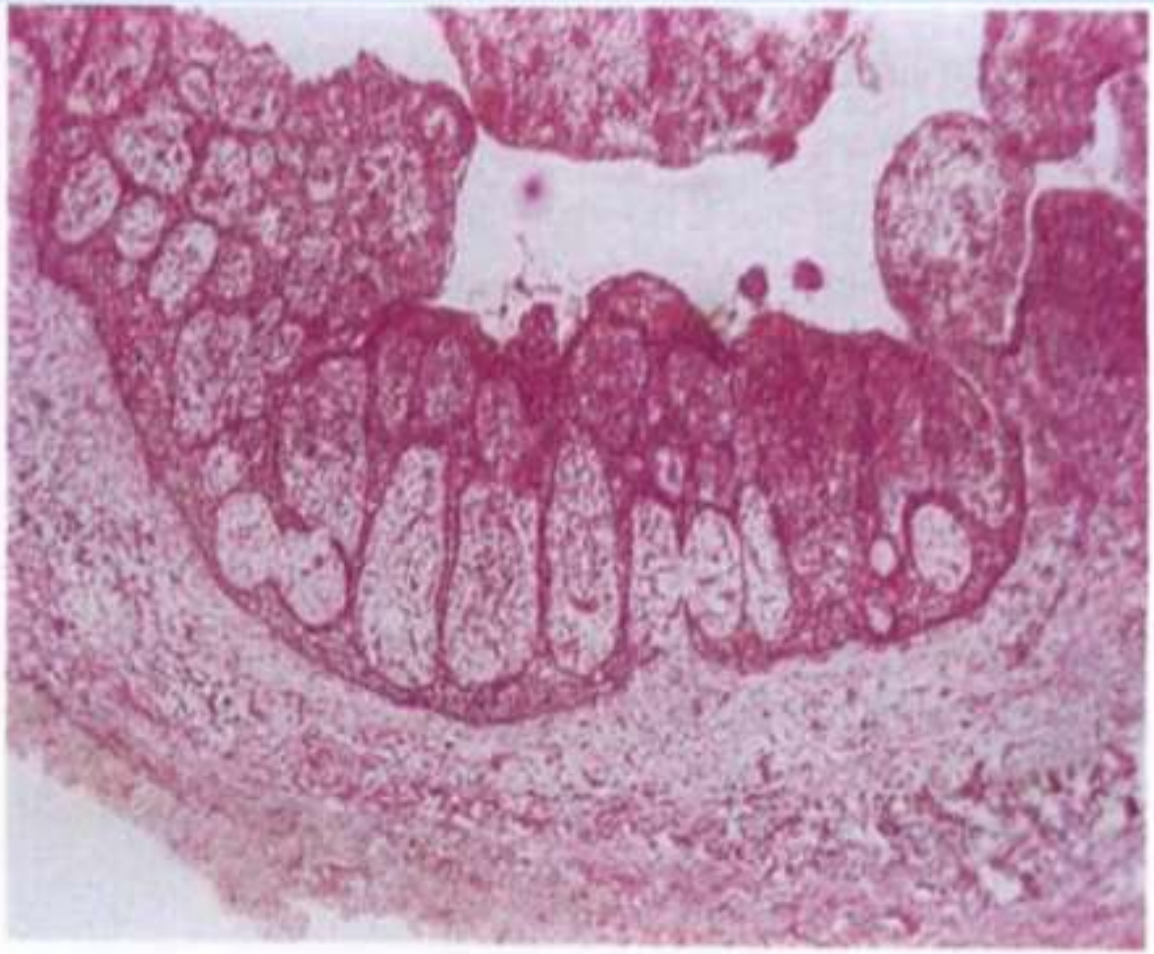

Fig. 7.5 Radicular cyst. The epithelial lining often assumes this arcaded pattern with numerous inflammatory cells beneath its surface.

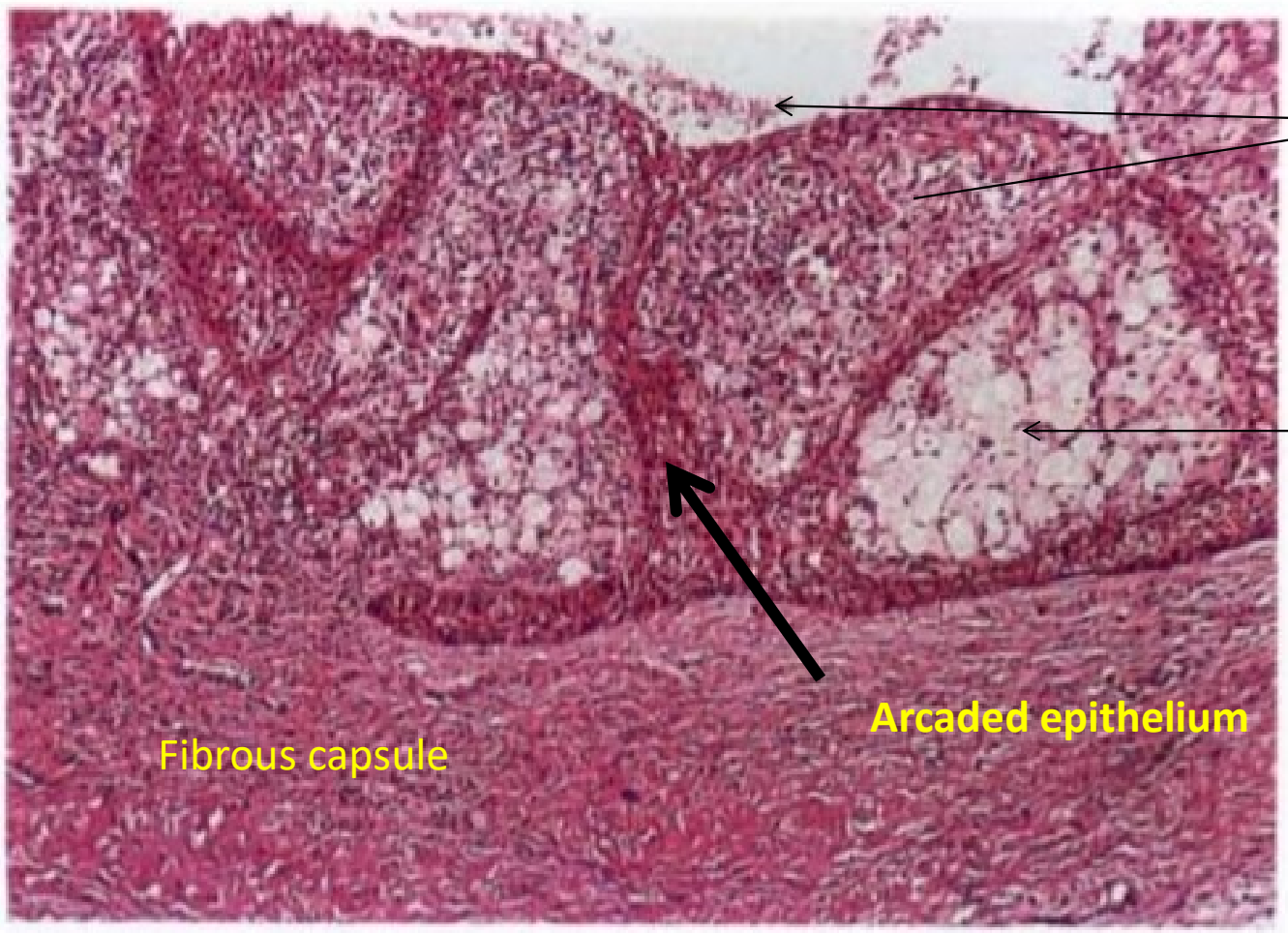

Fig. 7.6 Higher power of the lining of a radicular cyst. The arcaded epithelium contains numerous neutrophils emigrating into the lumen and there are pale staining areas of foamy macrophages in the inner wall.

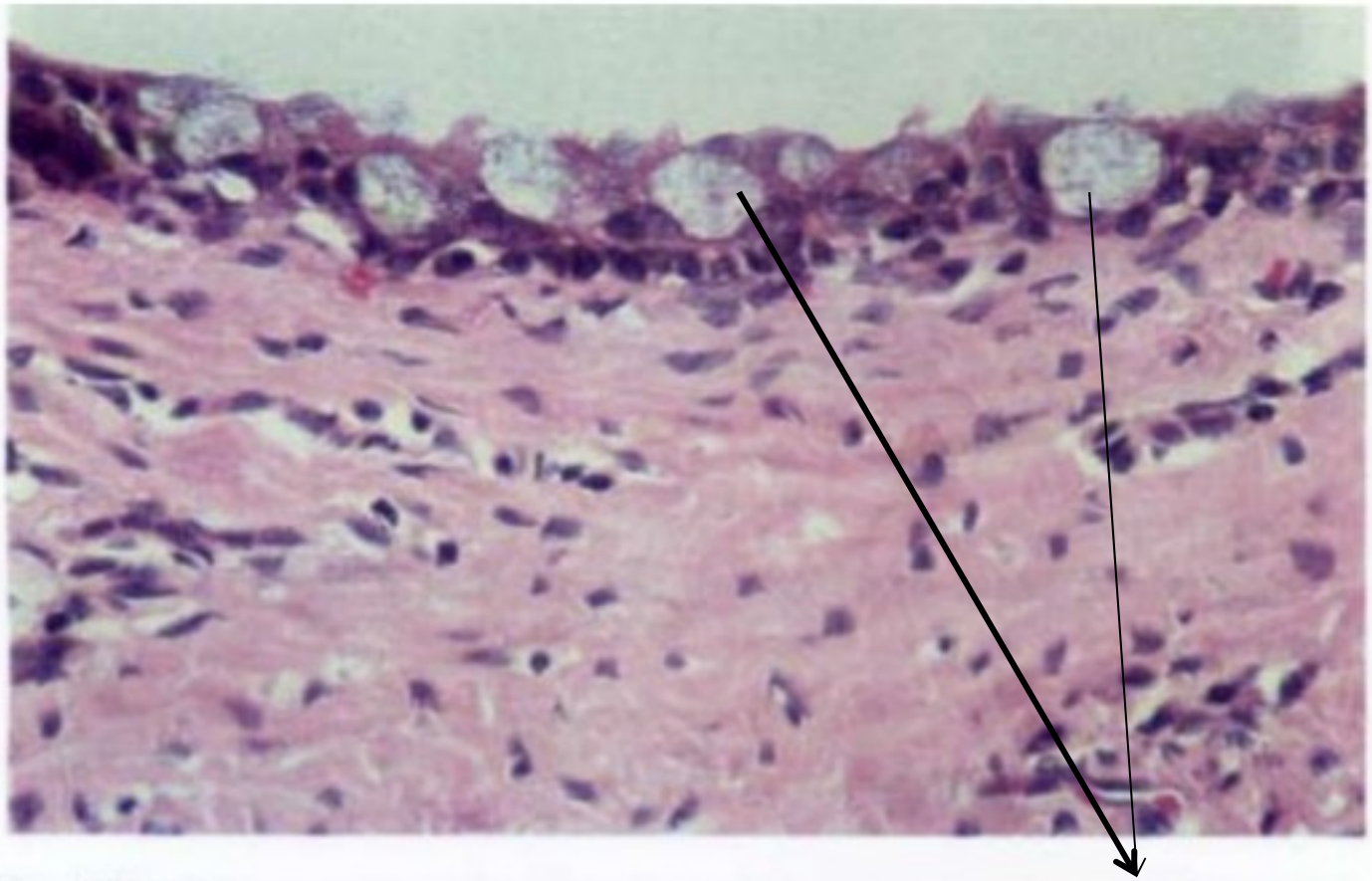

Fig. 7.8 Mucous metaplasia in a radicular cyst. The numerous goblet cells can be seen but are more typical of dentigerous cysts.

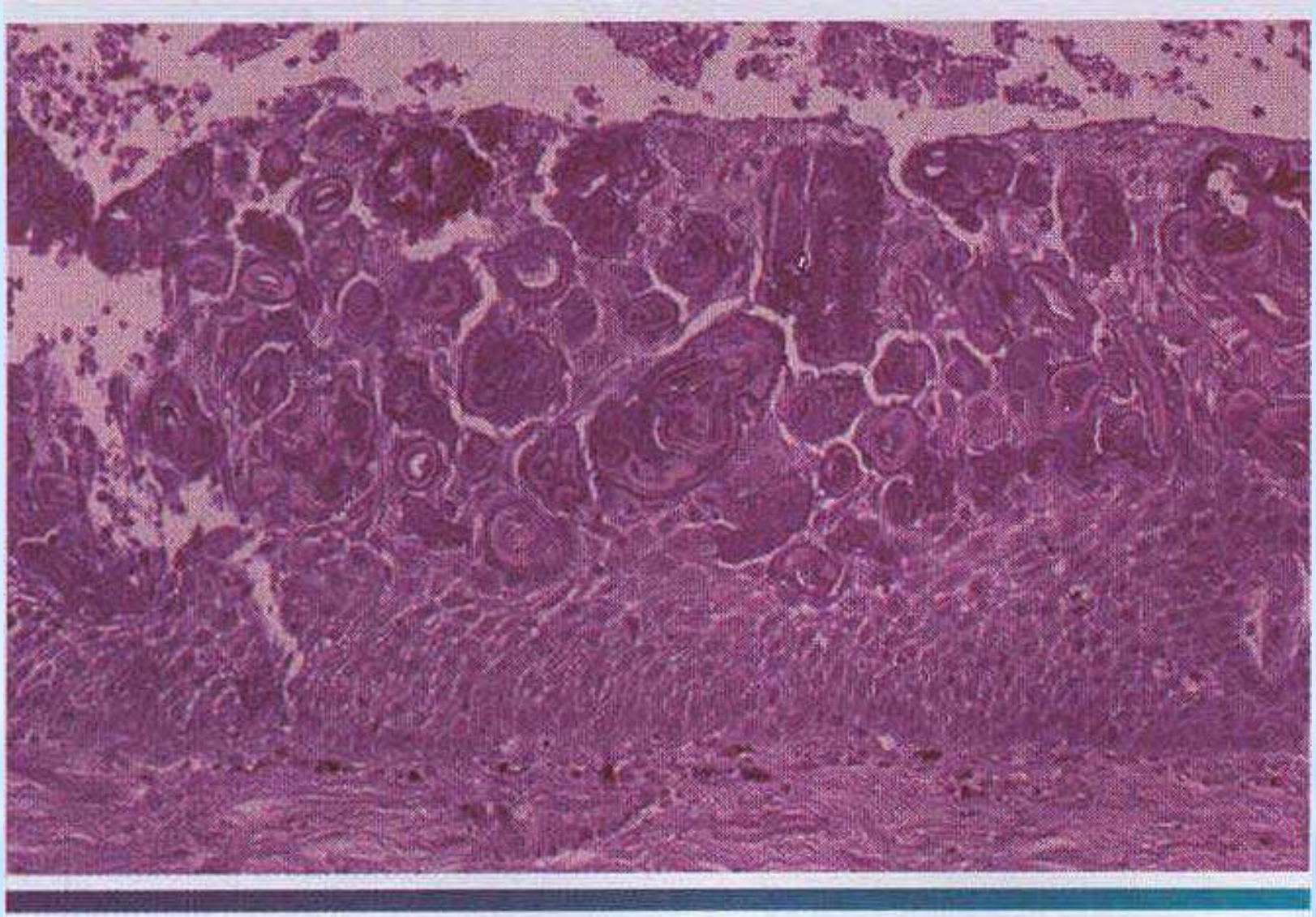

Periapical cyst .Squamous epithelial cyst lining exhibits numerous linear and arch-shaped Rushton bodies.

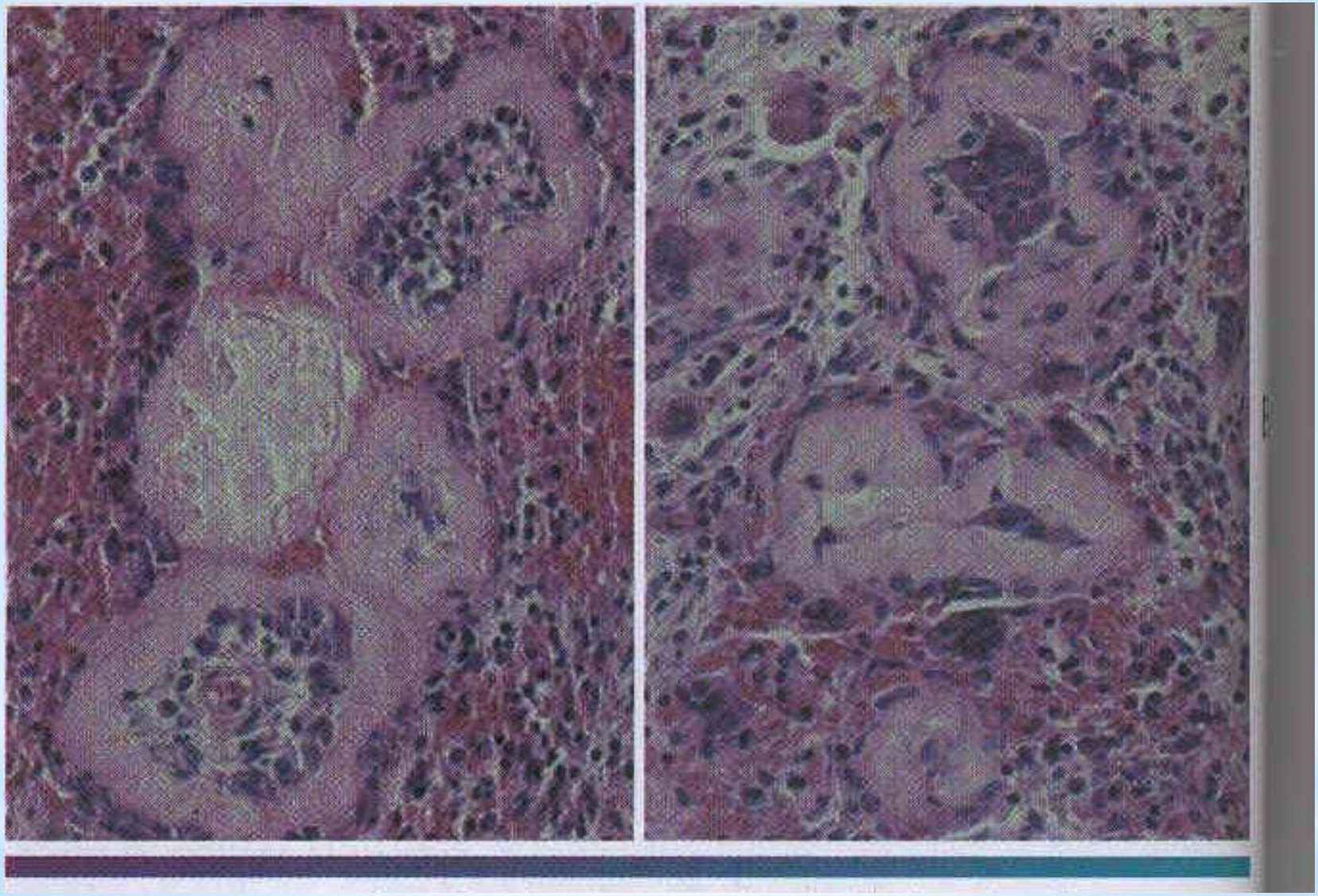

* Hyaline bodies. A, multiple hyaline bodies appearing as corrugated collagenous rings surrounding lymphocytes and plasma cells; note early hyaline body filled with serum. B, multiple hyaline bodies with numerous multinucleated giant cells within and around the corrugated collagenous rings.

RADICULAR CYST

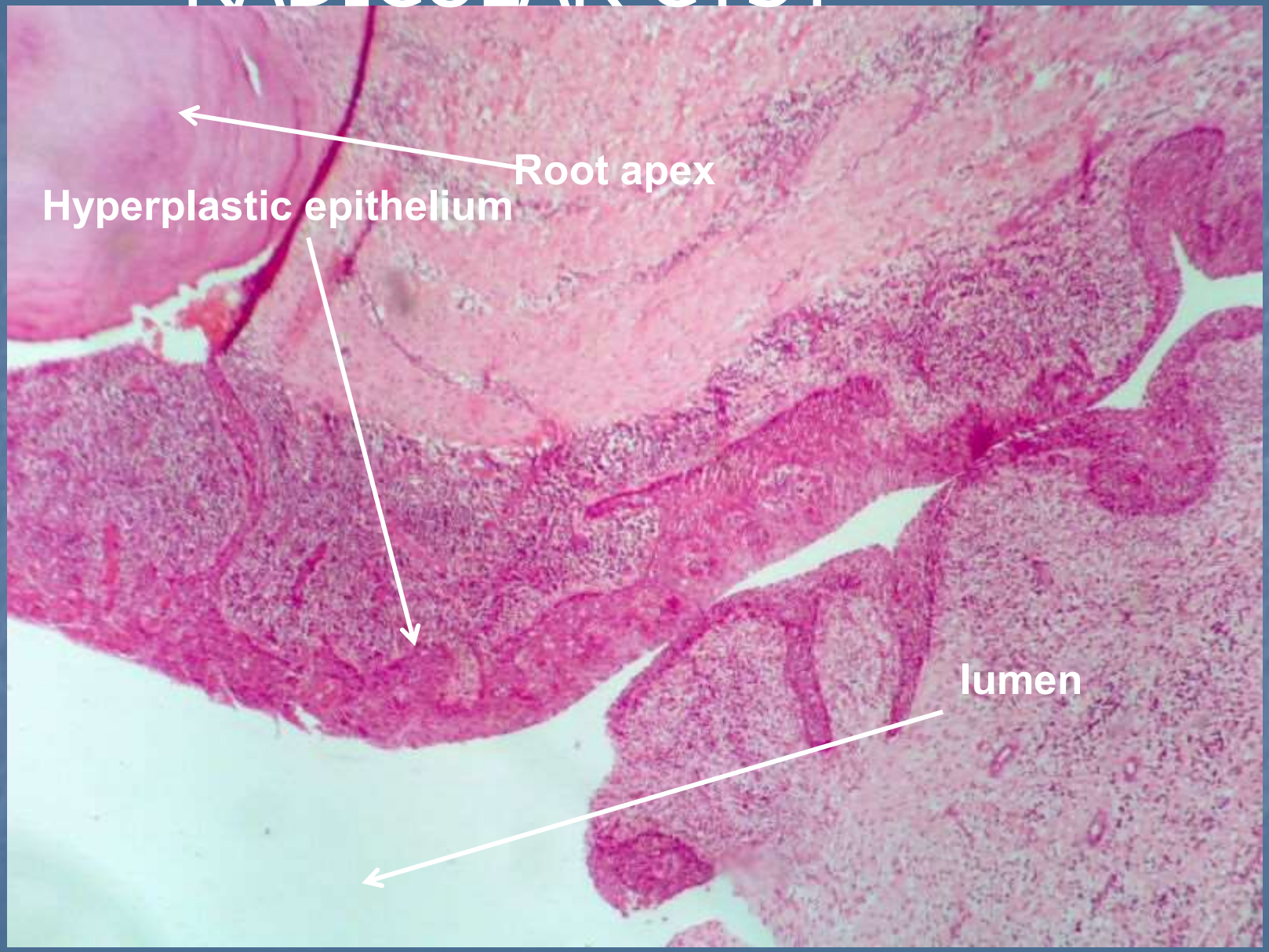

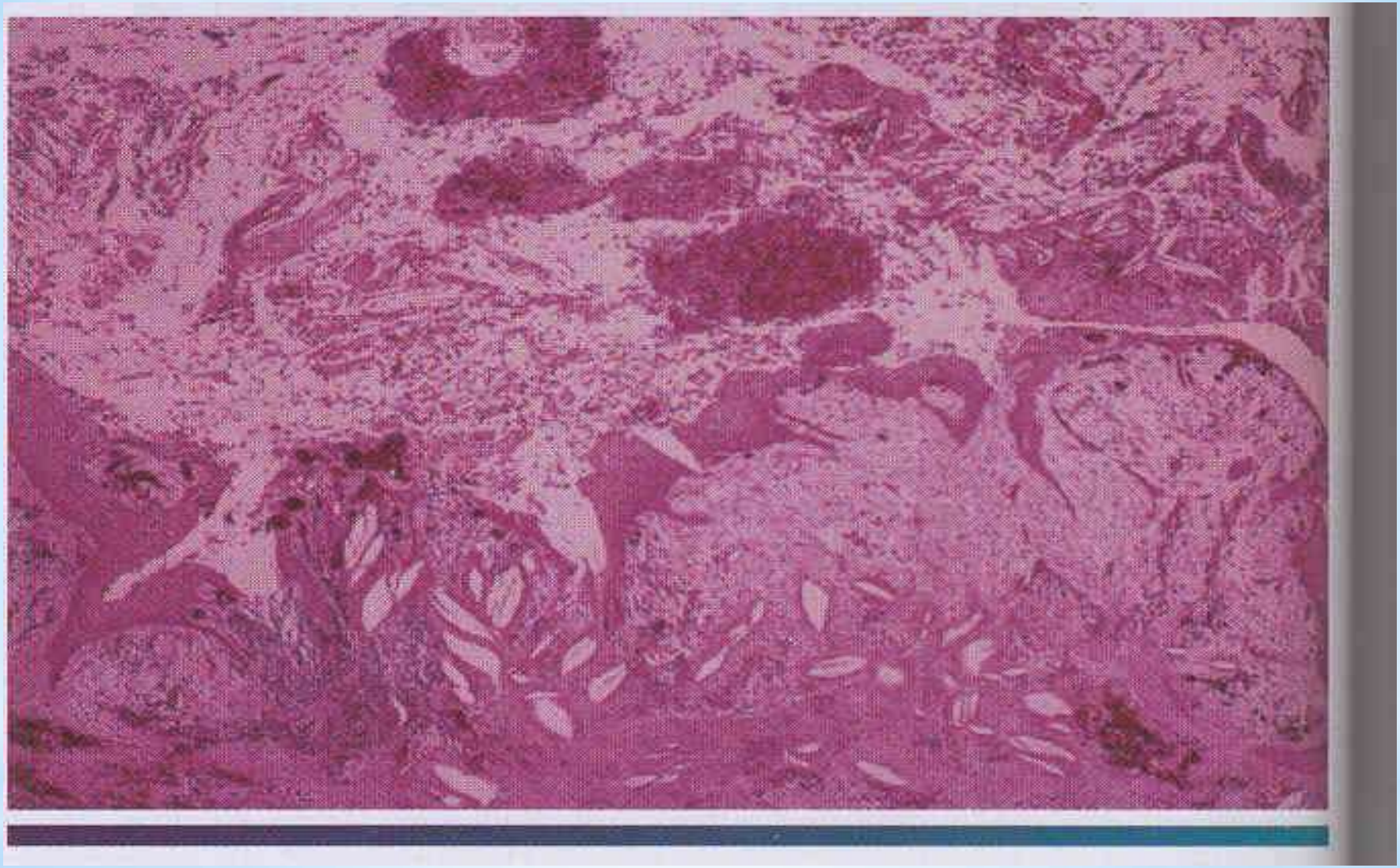

* Periapical cyst. Cyst lined by stratified squamous epithelium. Note connective tissue wall, which contains a chronic inflammatory infiltrate and scattered cholesterol clefts with associated multinucleated giant cells.

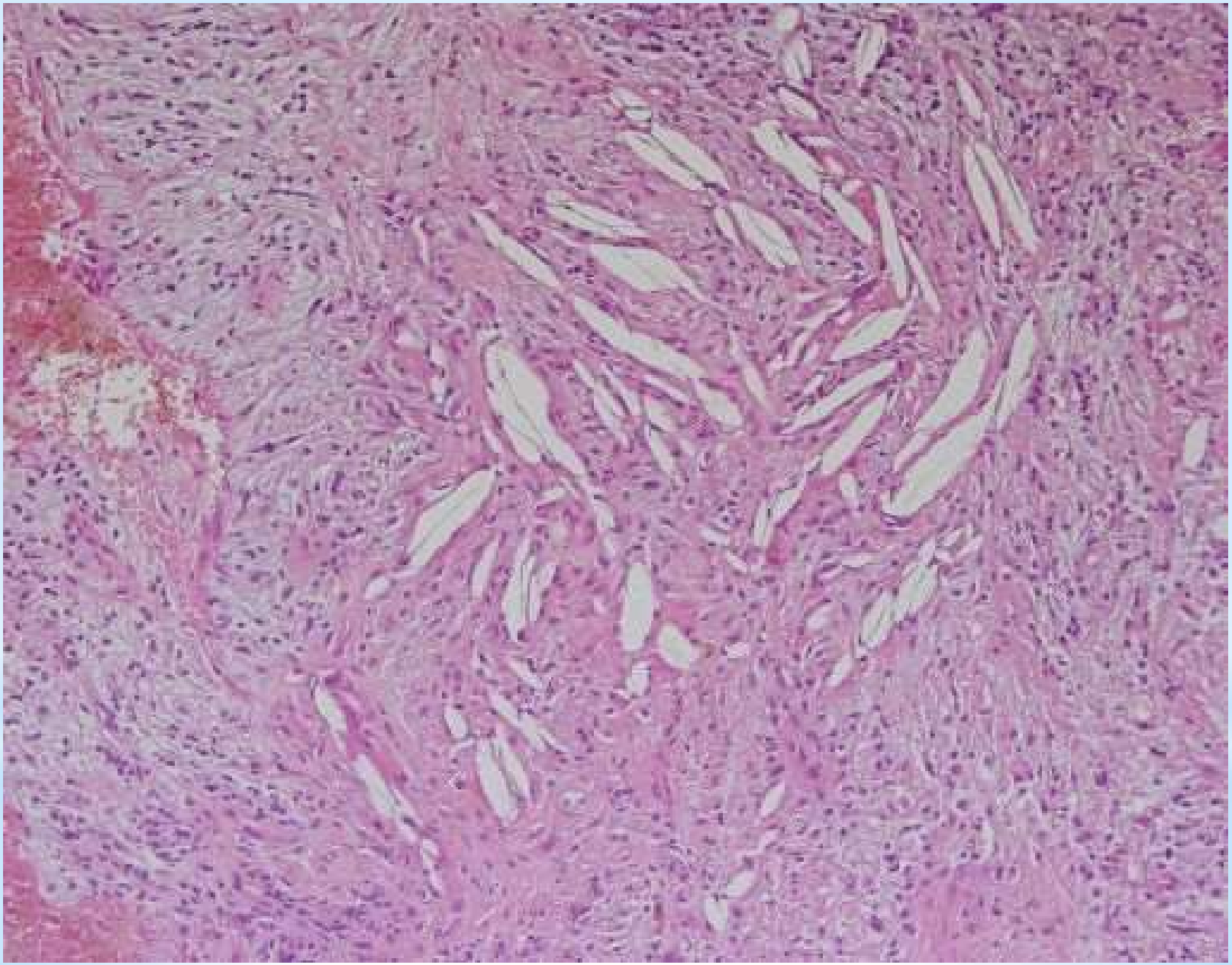

- Cholesterol crystals in form of clefts are often seen in the CT wall, inciting a foreign body giant cell reaction.

- Originate from disintegrating RBC's in presence of inflammation.

- Different types of dystrophic calcification are also seen in CT wall.

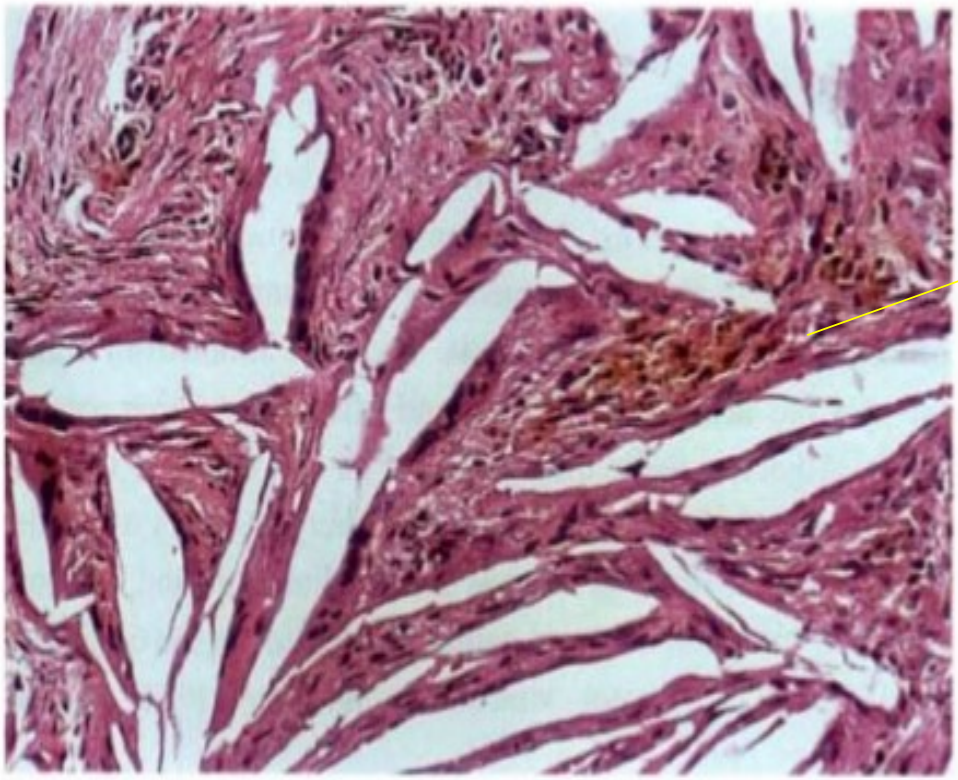

Giant cells

Fig. 7.10 Cholesterol clefts. Cholesterol has been dissolved out during preparation of the section, leaving clefts. The crystals are treated as foreign bodies and flattened multinucleate foreign body giant cells are seen along the edges of several clefts.

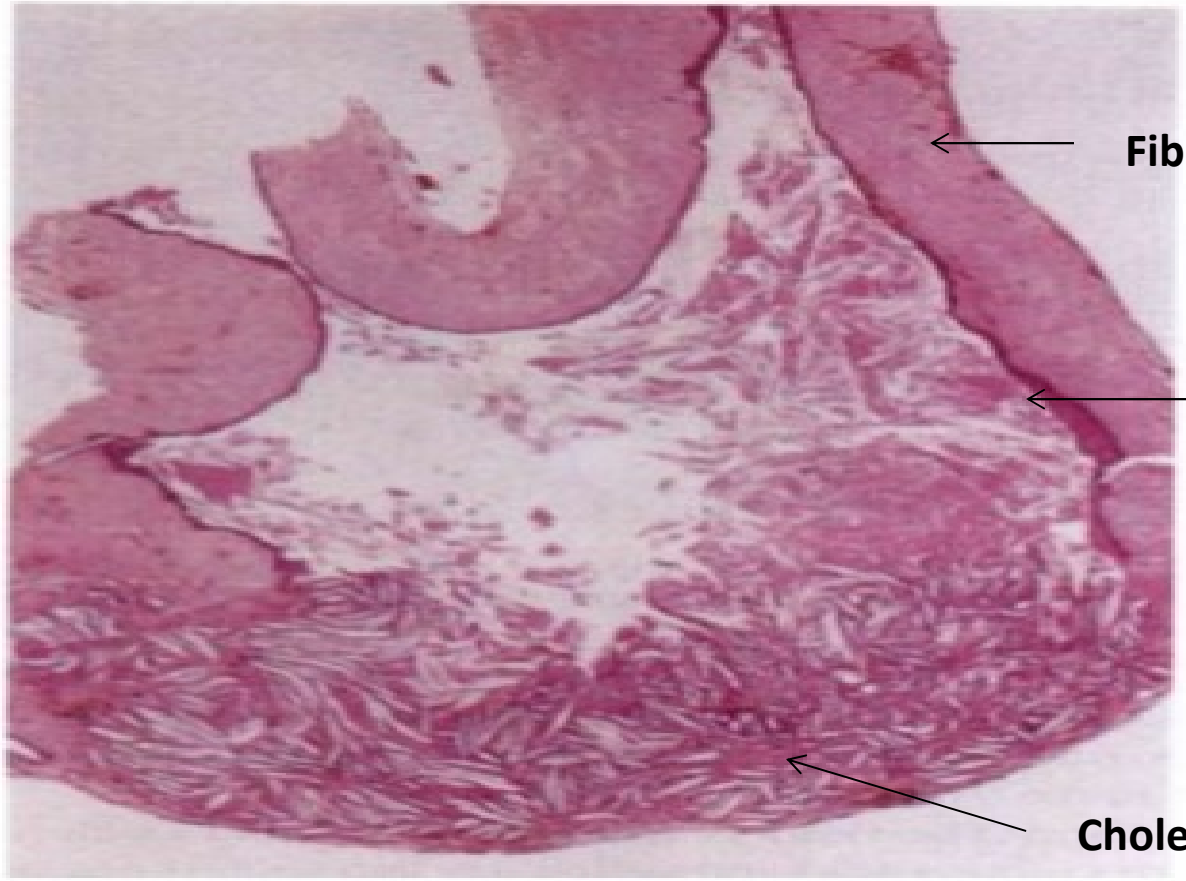

Fig. 7.9 Cholesterol clefts in a cyst wall. This low power view shows the relationship of cholesterol clefts to the cyst. Cholesterol crystals are formed in the fibrous wall. The epithelium overlying this focus has broken down and the cholesterol leaks into the cyst contents. Elsewhere the lumen is lined by a flattened layer of squamous epithelium.

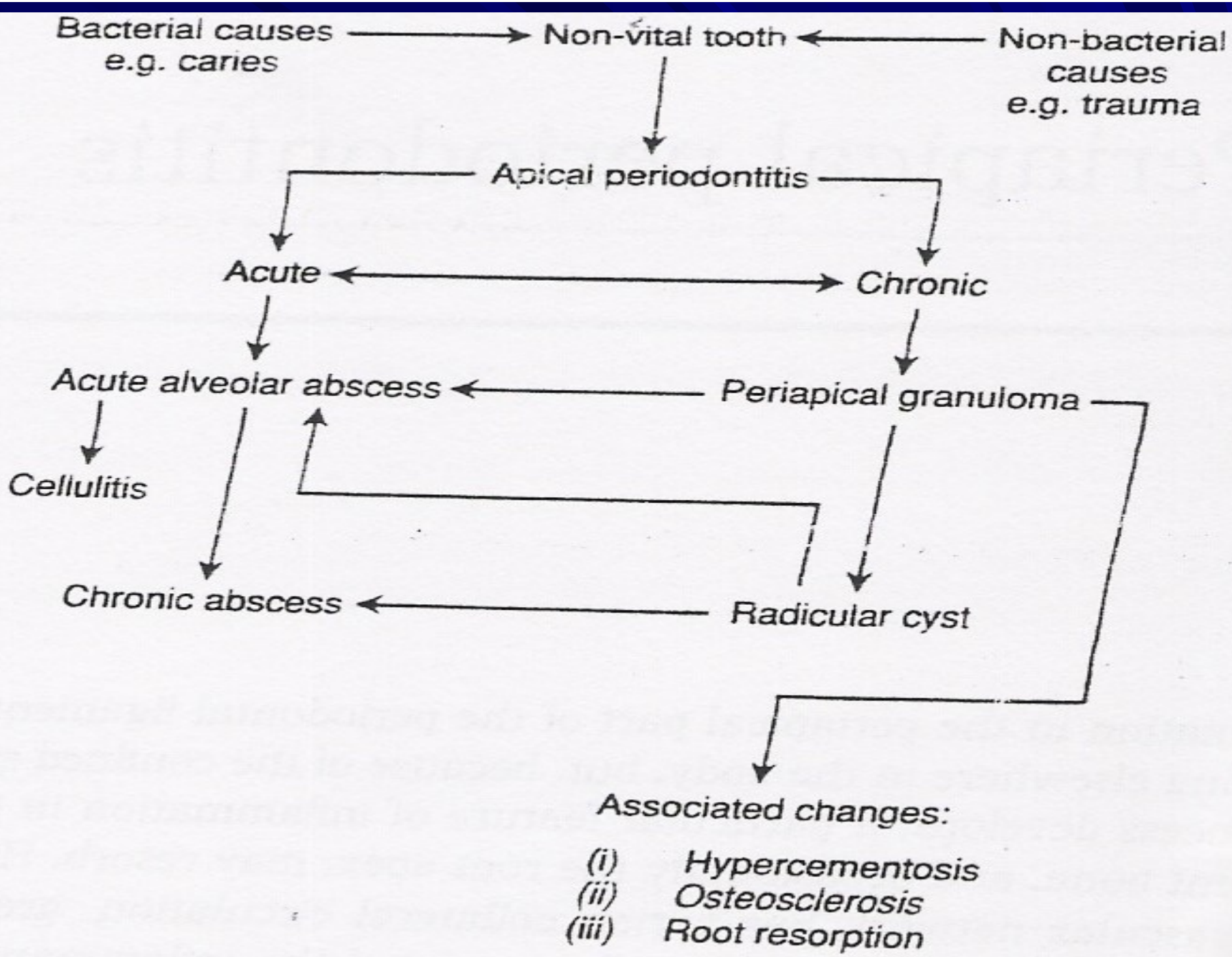
Bacterial causes
e.g. caries
Non-vital tooth
Non-bacterial
causes
e.g. trauma
Apical periodontitis
Acute
Chronic
Acute alveolar abscess
Periapical granuloma
Cellulitis
Chronic abscess
Radicular cyst
Associated changes:
(i) Hypercementosis
(ii) Osteosclerosis
(iii) Root resorption